

THE JOURNAL OF BONE & JOINT SURGERY

JB&JS

This is an enhanced PDF from The Journal of Bone and Joint Surgery

The PDF of the article you requested follows this cover page.

Extensor Mechanism Allograft Reconstruction After Total Knee Arthroplasty

R. Stephen J. Burnett, Richard A. Berger, Craig J. Della Valle, Scott M. Sporer, Joshua J. Jacobs, Wayne G. Paprosky and Aaron G. Rosenberg
J Bone Joint Surg Am. 2005;87:175-194. doi:10.2106/JBJS.E.00442

This information is current as of March 17, 2009

Reprints and Permissions

Click here to [order reprints or request permission](#) to use material from this article, or locate the article citation on jbjs.org and click on the [Reprints and Permissions] link.

Publisher Information

The Journal of Bone and Joint Surgery
20 Pickering Street, Needham, MA 02492-3157
www.jbjs.org

Extensor Mechanism Allograft Reconstruction After Total Knee Arthroplasty

Surgical Technique

BY R. STEPHEN J. BURNETT, MD, FRCS(C), RICHARD A. BERGER, MD, CRAIG J. DELLA VALLE, MD, SCOTT M. SPORER, MD, JOSHUA J. JACOBS, MD, WAYNE G. PAPROSKY, MD, AND AARON G. ROSENBERG, MD

Investigation performed at the Department of Orthopedic Surgery, Rush University Medical Center, Chicago, Illinois

The original scientific article in which the surgical technique was presented was published in JBJS Vol. 86-A, pp. 2694-2699, December 2004

INTRODUCTION

Extensor mechanism disruption is a devastating complication of total knee arthroplasty. Multiple techniques for repair or reconstruction of a deficient extensor mechanism have been described in association with total knee arthroplasty; however, few have been able to reliably restore a functional extensor mechanism¹. Despite encouraging results reported for direct repair in native knees, attempts at primary repair following a total knee arthroplasty rarely restore extensor function. The use of local autogenous tissue to augment a primary repair has been recommended. These patients have frequently undergone multiple previous knee procedures, and these local autogenous tissues may be compromised and unsuitable for use.

Emerson et al.^{2,3} reported on the use of a complete knee extensor mechanism allograft in total knee arthroplasty to reconstruct the deficient extensor mechanism. Although the early clinical results were promising, extensor lag occurred early. Nazarian and Booth⁴ modified the technique described by Emerson et al., recommending that the allograft be tightly tensioned in full extension, and they reported improved early results. The host tissue-allograft junctions recently have been studied⁵, and the findings have provided useful information in support of this technique.

In the present report, we describe the surgical technique that we have modified and currently use⁶ to reconstruct the deficient extensor mechanism with an extensor mechanism allograft that is tightly tensioned with the knee in full extension. The critical concepts, pitfalls, and technical aspects of this technique are presented.

ABSTRACT

BACKGROUND:

Disruption of the extensor mechanism is an uncommon but catastrophic complication of total knee arthroplasty. We evaluated two techniques of reconstructing a disrupted extensor mechanism with the use of an extensor mechanism allograft in revision total knee arthroplasty.

METHODS:

Twenty consecutive reconstructions with the use of an extensor mechanism allograft consisting of the tibial tubercle, patellar tendon, patella, and quadriceps tendon were performed. The first seven reconstructions (Group I) were done with the allograft minimally tensioned. The thirteen subsequent procedures (Group II) were performed with the allograft tightly tensioned in full extension. All surviving allografts were evaluated clinically and radiographically after a minimum duration of follow-up of twenty-four months.

continued

ABSTRACT | continued**RESULTS:**

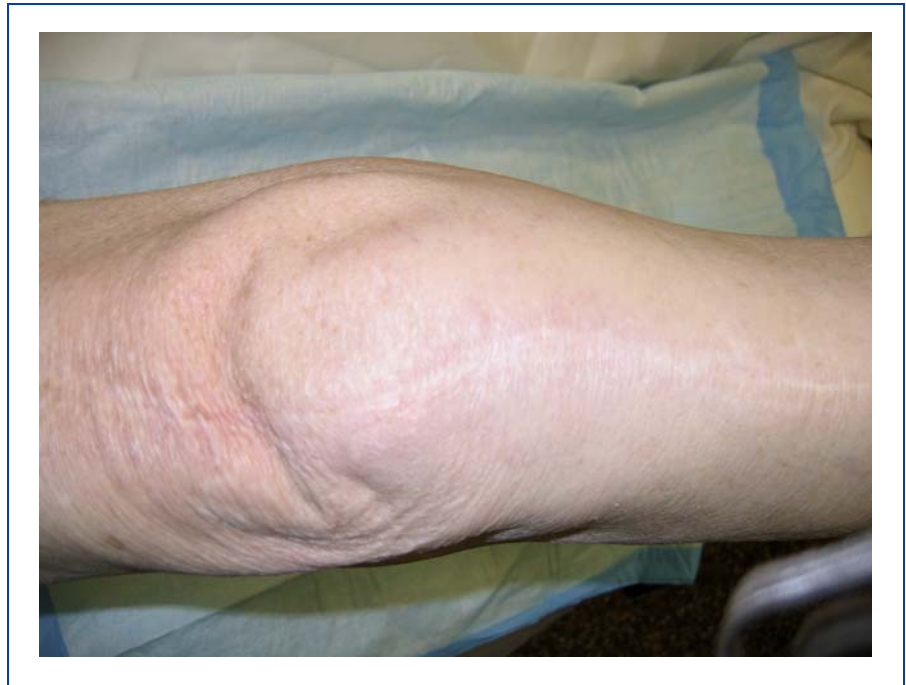All of the reconstructions in Group I were clinical failures, with an average postoperative extensor lag of 59° (range, 40° to 80°) and an average postoperative Hospital for Special Surgery knee score of 52 points. All thirteen reconstructions in Group II were clinical successes, with an average postoperative extensor lag of 4.3° (range, 0° to 15°) ($p < 0.0001$) and an average Hospital for Special Surgery score of 88 points. Postoperative flexion did not differ significantly between Group I (average, 108°) and Group II (average, 104°) ($p = 0.549$).

CONCLUSIONS:

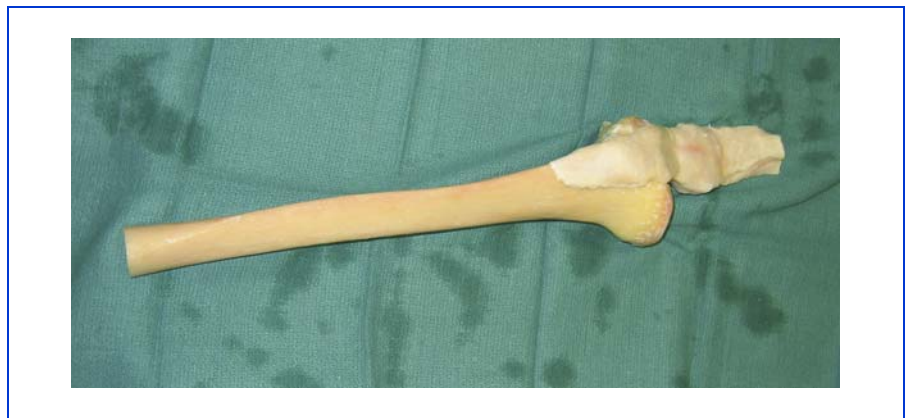The results of reconstruction with an extensor mechanism allograft after total knee arthroplasty depend on the initial tensioning of the allograft. Loosely tensioned allografts result in a persistent extension lag and clinical failure. Allografts that are tightly tensioned in full extension can restore active knee extension and result in clinical success. On the basis of the number of knees that we studied, there was no significant loss of flexion. Use of an extensor mechanism graft for the treatment of a failure of the extensor mechanism will be successful only if the graft is initially tensioned tightly in full extension.

INITIAL EVALUATION

A deficient extensor mechanism in association with a total knee arthroplasty is one of the most challenging problems that the orthopaedic surgeon who performs joint replacement surgery

**FIG. 1**

Assessment of prior incisions over the knee and a careful examination are essential preoperatively when considering revision surgery.

**FIG. 2**

A complete fresh-frozen, nonirradiated knee extensor mechanism allograft that includes the tibia, patellar tendon, patella, and quadriceps tendon is used.

may encounter. The patient is initially evaluated with a history, directed physical examination of the knee and extremity, radiographs, and adjunctive investigations. The history should focus on obtaining information about

prior extensor mechanism procedures or surgery and the prior and current function of the knee. Symptoms of instability, giving-way, and an inability to extend the knee should be sought. The nature of previous surgeries and

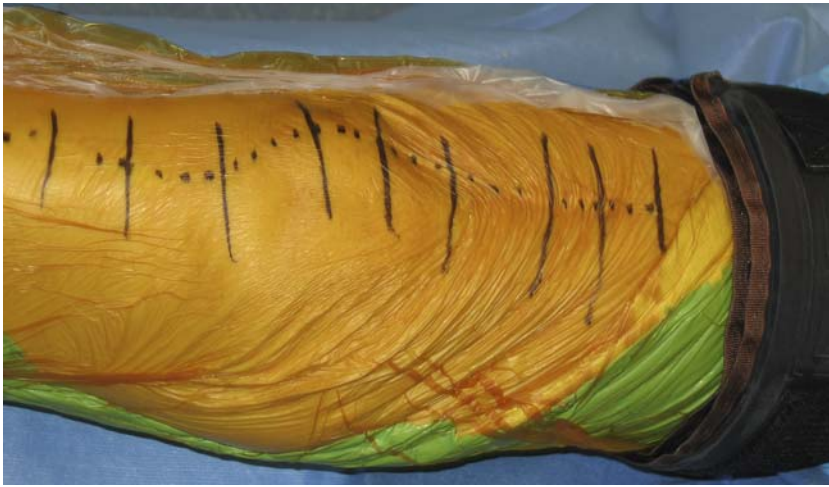

FIG. 3

Use of the previous incision is preferred. We use a sterile tourniquet as it is easily removed for the allograft-host proximal graft repair.

to passively extend the knee are noted. The tracking of the extensor mechanism during range-of-motion testing should be examined closely, as malrotation of the components of the total knee arthroplasty may be a factor in the extensor mechanism failure. Radiographs are evaluated for component alignment, fixation, sizing, remaining host-bone stock, and the design of components. The extensor mechanism and patellar position are evaluated for patella infera, patella alta, and the presence or absence of a patella. In addition, the presence of heterotopic ossification involving the extensor mecha-

the duration of extensor dysfunction should be determined. Prior operative reports should be reviewed and scrutinized for the extensor mechanism and how it was managed in previous surgeries. A history of infection—remotely or in association with prior surgery of the knee—warrants further investigation. Medical comorbidities or immunosuppressive therapy that may impact on wound-healing should be sought. On physical examination, evaluation of the gait pattern and the use of walking aids are assessed. Prior incisions over the knee (Fig. 1) and active and passive range of motion are recorded. The presence of an extensor lag should be carefully measured, and the passive amount of full extension that is able to be demonstrated should be noted. The presence of a flexion contracture and the inability

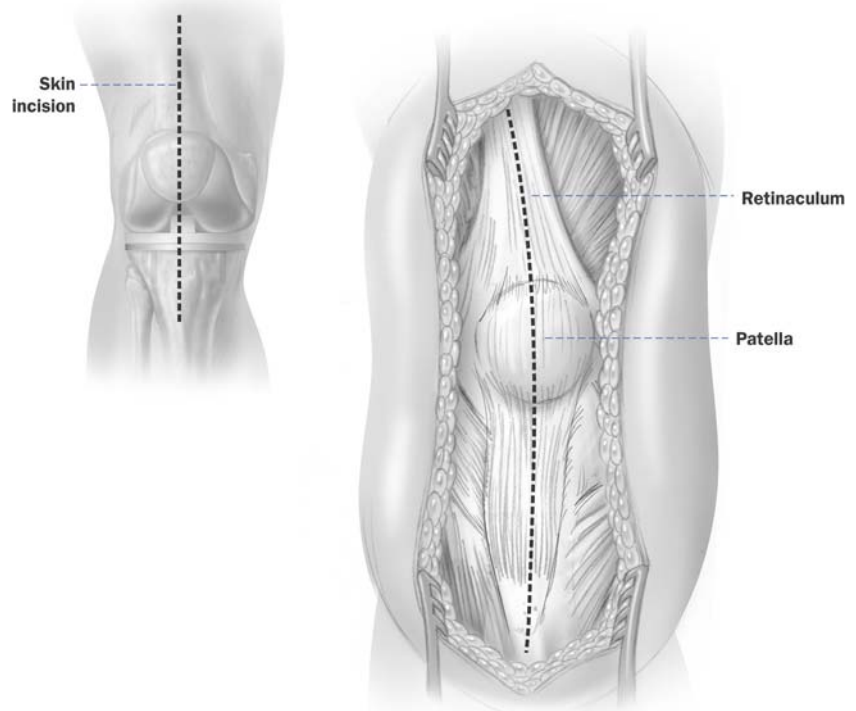


FIG. 4

The host extensor mechanism is sharply dissected longitudinally in the midline, through the patellar tendon and quadriceps tendon.

nism is noted. The presence of suture anchors or staples around the insertion of the patellar tendon into the tibial tubercle is often an ominous radiographic sign. Patellar tracking is evaluated on the axial radiograph. If there is any concern about malrotation of the components, we recommend an axial computed tomography scan of the femoral and tibial components to evaluate for component internal malrotation⁷. The erythrocyte sedimentation rate and serum C-reactive protein level are measured to evaluate for infection. If these are elevated, a knee aspiration is performed for cell count and synovial fluid culture.

Decision to Reconstruct the Extensor Mechanism with Use of an Extensor Mechanism Allograft

Once the diagnosis and etiology of a deficient extensor mechanism is made, we discuss the surgical options with each patient. The indications and contraindications are carefully reviewed. Ongoing infection or repeated unsuccessful staged reimplantation procedures with persistent infection are contraindications to this procedure. The inability to comply with postoperative immobilization and a directed physical therapy program are also contraindications. In these instances, bracing and nonoperative treatment or knee arthrodesis are discussed with the patient. If the patient is a candidate for surgery, the procedure and postoperative rehabilitation are discussed preoperatively. If

FIG. 5

The remaining patella or remnant is split in the midline with a saw, in line with the proximal and distal split.

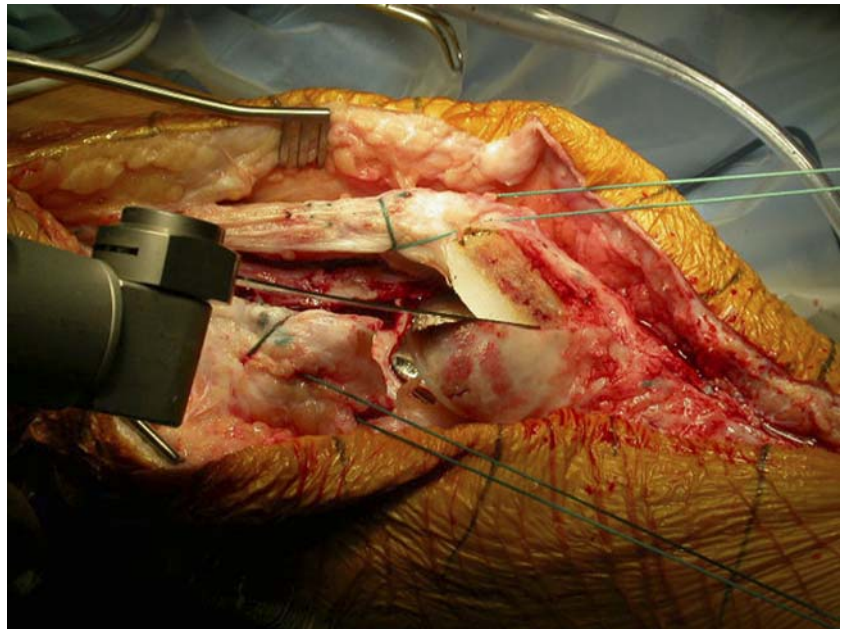
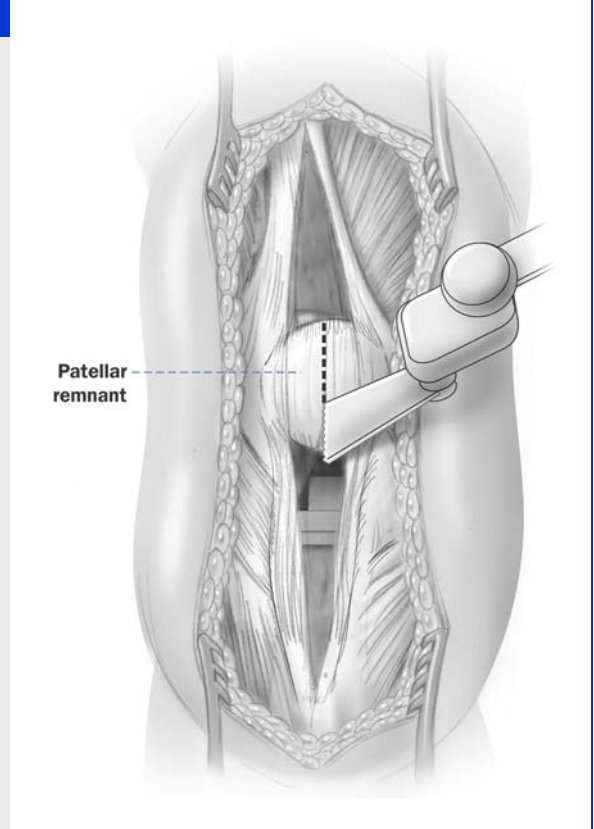


FIG. 6

A saw is used to split the patella from anterior to posterior in a longitudinal fashion, in line with the extensor mechanism arthrotomy.

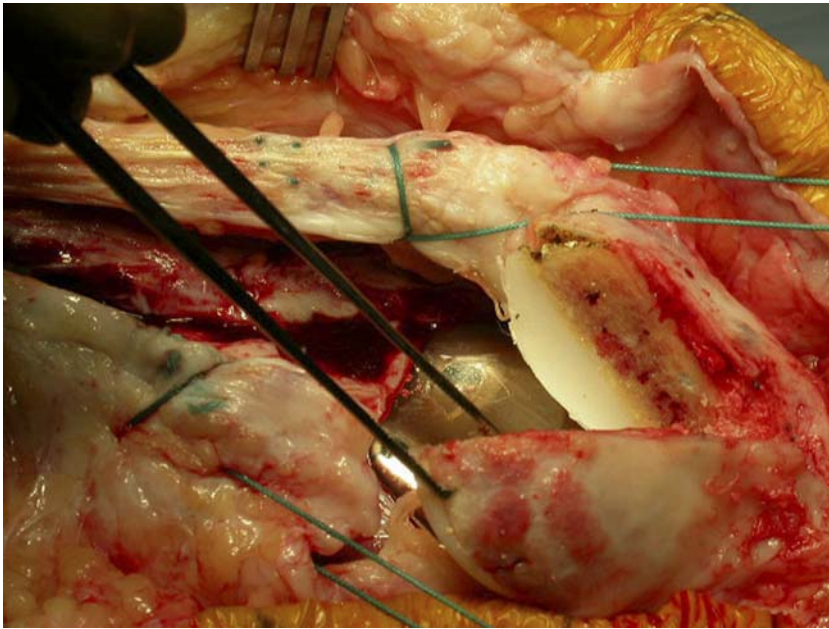


FIG. 7

The soft tissues around the patella are preserved in continuity with the retinaculum on the medial and lateral sides of the two fragments.

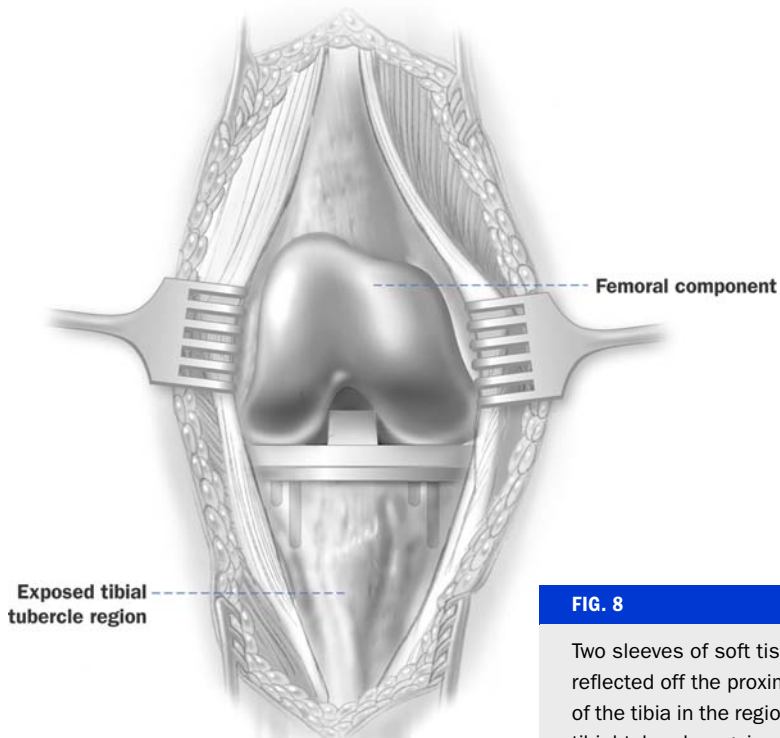


FIG. 8

Two sleeves of soft tissue are reflected off the proximal part of the tibia in the region of the tibial tubercle, again maintaining two flaps for later closure.

the patient has an intact native patella and a deficient patellar tendon, alternative allograft extensor mechanism reconstructions with the use of an Achilles tendon-allograft calcaneal bone block⁸ may also be considered. We always plan to be prepared to revise and address malrotated total knee arthroplasty components at the time of revision surgery.

Allograft Extensor Mechanism

Preoperatively, we order an allograft extensor mechanism of the entire knee that includes the tibia or a large portion of the proximal part of the tibia, the patellar tendon, the patella, and at least 5 cm of quadriceps tendon (Fig. 2). The allografts are fresh-frozen, nonirradiated specimens (Allosource, Centennial, Colorado). We prefer the fresh-frozen over the freeze-dried allografts, given the results previously described by Emerson et al.^{2,3} and concerns that freeze-drying may weaken the allograft tissue, leading to complications and failure. The potential to generate a greater risk of a host immune response than occurs with fresh-frozen specimens has also been a concern. Before the patient comes into the operating room and before the induction of anesthesia, we visually inspect the allograft to ensure that there is an adequate specimen. Specifically, there must be a proximal tibial allograft that will allow a bone-block harvest of at least 5 cm attached to the patellar ten-

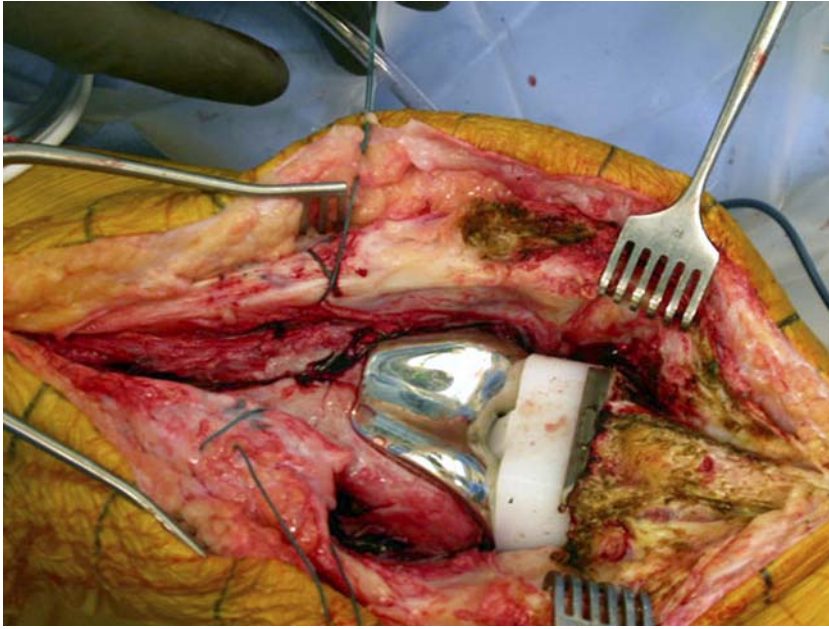


FIG. 9

Medial and lateral sleeves have been created, allowing direct exposure to the implants and the anterior aspect of the tibia and tubercle.

use of a previous incision is recommended when present. If multiple incisions are present, we use the most lateral incision closest to the midline, in order to preserve blood supply to the skin. Often these are knees that have had multiple operations and may have undergone a previous gastrocnemius flap or other soft-tissue coverage procedure. In this instance, we are careful not to disrupt the blood supply to this coverage and we have a plastic reconstructive surgeon available to assist during the exposure. The dissection is carried down in the midline with conservative elevation of skin and subcutaneous flaps. The retinaculum and extensor mechanism are then exposed. A midline inci-

don and at least 5 cm of allograft quadriceps tendon proximally.

SURGICAL TECHNIQUE

Patient Positioning

We place the patient supine on the operating table, with a sterile pneumatic tourniquet around the thigh and a padded bump beneath the trochanter. The leg is prepared and draped free, and the foot is held in a leg holder during the procedure to allow variable amounts of flexion and extension.

Exposure of the Knee

The pneumatic tourniquet is inflated after exsanguination with an Esmarch bandage and flexion of the knee. Previous incisions are marked (Fig. 3). We prefer a midline skin incision; however,

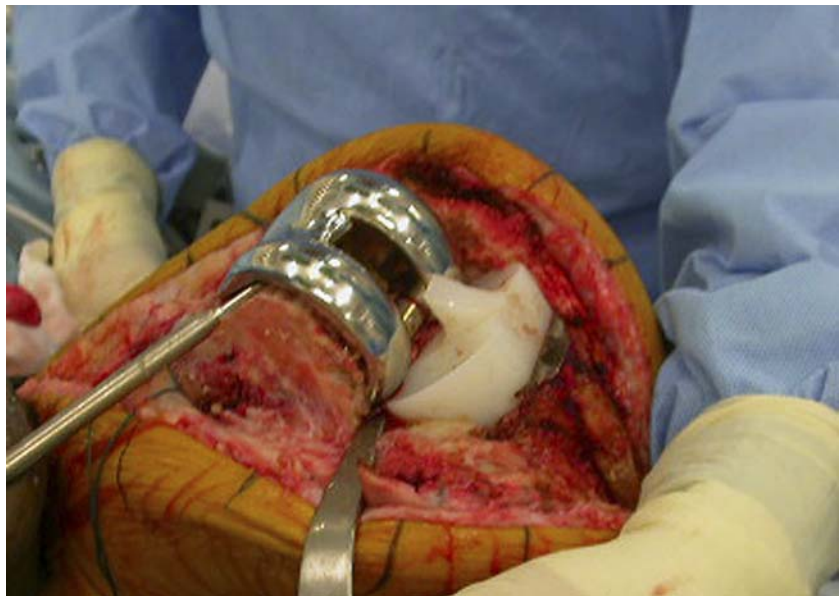

FIG. 10

Removal of a malrotated femoral component. If malrotated components are left undressed, extensor mechanism maltracking will continue, with increased stress on the allograft and early failure.

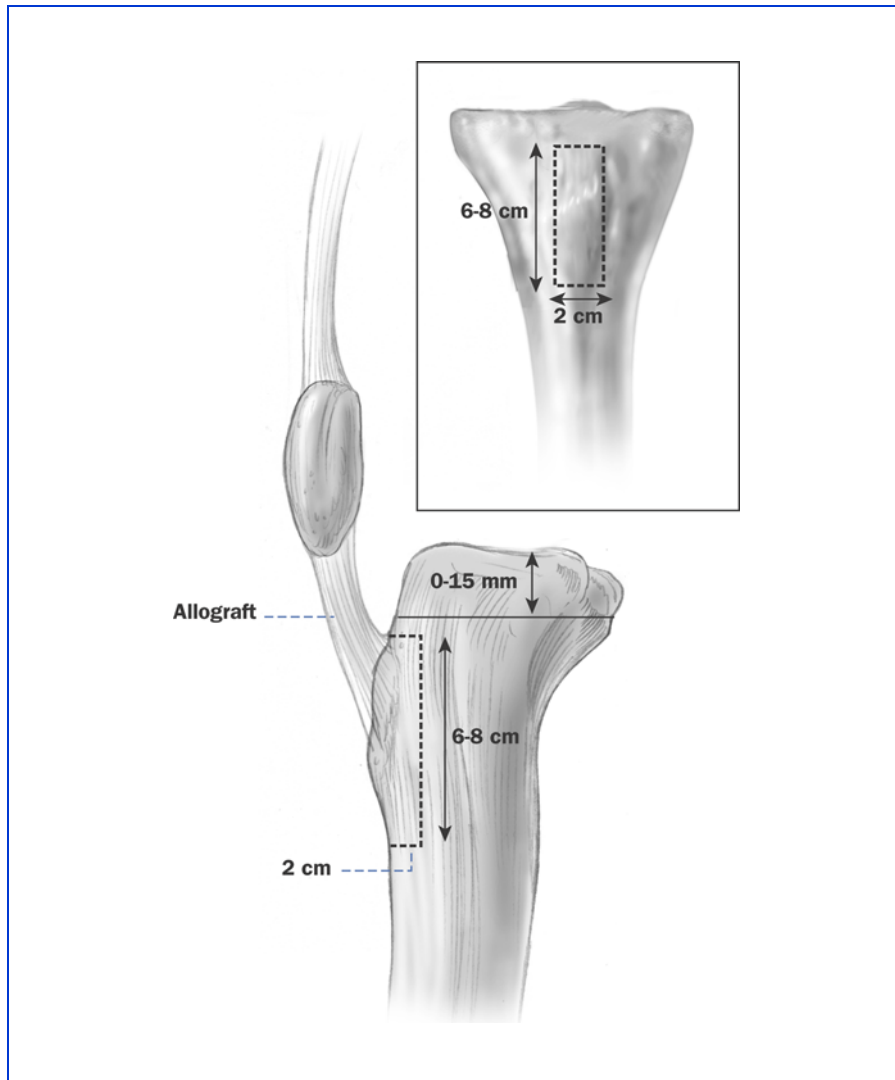


FIG. 11

The allograft tibial block is marked for a rectangular cut of 6 to 8 x 2 x 2 cm.

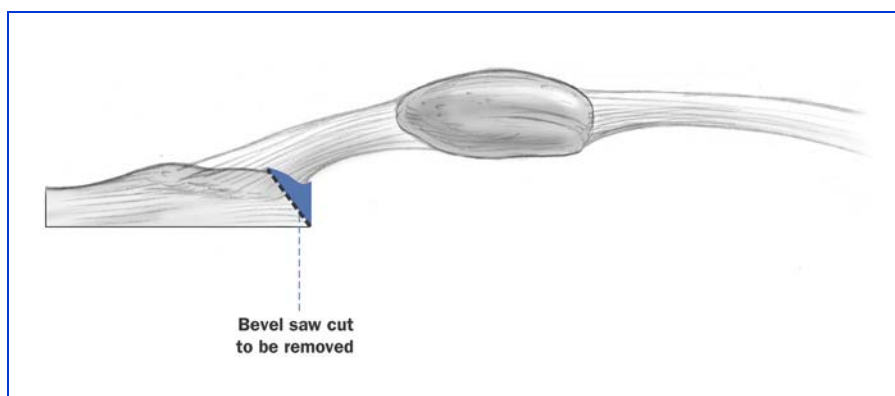


FIG. 12

The rectangular block is then marked for a later bevel cut proximally to create the dovetail.

sion is performed through the remaining extensor mechanism (the quadriceps tendon and patellar tendon or scar tissue), creating medial and lateral flaps of retinaculum and exposing the joint (Fig. 4). Culture specimens are obtained and sent to the microbiology laboratory, and synovial fluid is assessed for cell count. If there is a native patella or a remnant, it is osteotomized in a longitudinal fashion in the midline (Fig. 5), in line with the midline soft-tissue retinacular incision (Figs. 6 and 7). The patellar bone is then shelled out and carefully removed, preserving the soft tissues in continuity with the medial and lateral retinacular flaps. This bone is kept for autogenous bone graft as necessary. The medial and lateral gutters and suprapatellar pouch are recreated. The midline incision is carried proximally into the host quadriceps, again maintaining a medial and lateral sleeve of tissue for later closure. The midline incision is carried over the host tibial tubercle with elevation of medial and lateral soft-tissue flaps (Figs. 8 and 9).

Total Knee Arthroplasty Component Revision and Reimplantation

Revision total knee arthroplasty then proceeds as necessary. Rotation of the femoral and tibial components is assessed, and our threshold for revision of malrotated components is very low, as they can contribute to extensor mechanism maltracking (Fig. 10). Balancing of flexion and ex-

tension gaps is then performed, with careful attention to obtaining full passive extension of the knee. Trial components are removed, and definitive components are implanted in a routine fashion. The final polyethylene liner is inserted prior to insertion of the extensor mechanism allograft. We have used this procedure with primary cruciate-retaining, posterior stabilized, revision constrained condylar designs, and constrained hinge knee designs. If stemmed components are being inserted, it may be preferable to prepare the host tibial bone trough and place the fixation wires through the tibia at this stage, followed by insertion of the stemmed tibial component.

The revision total knee arthroplasty implants are now in place, and the host tissues are next prepared to accept the extensor mechanism allograft.

Allograft Preparation on the Back Table

Simultaneous with the revision or placement of the total knee arthroplasty components, the allograft specimen may be prepared on the back table. The host tibial trough is not made until we have harvested the allograft tibial block, in order to ensure a press-fit of our allograft tibial block. We first mark with a marking pen over the allograft tibial tubercle and proximal part of the tibia our planned harvest of the allograft tibial bone block, in a rectangular fashion. The length of the block should be ap-

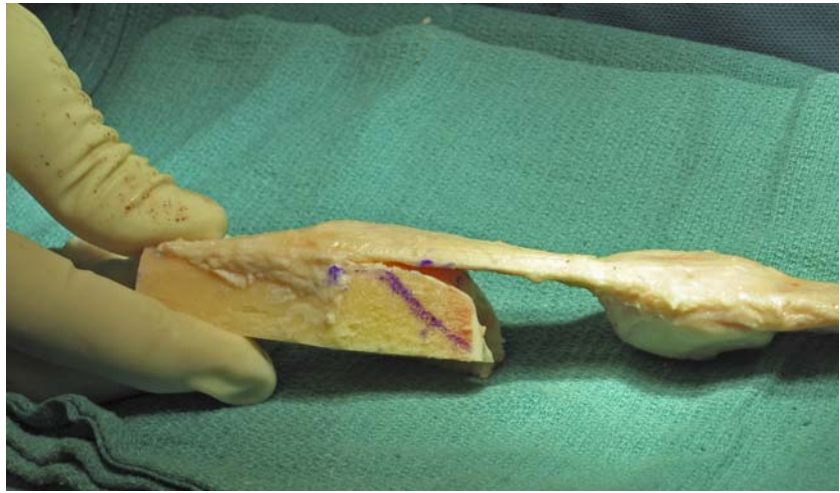


FIG. 13

Photograph of the rectangular tibial cut marked for the finishing bevel cut.

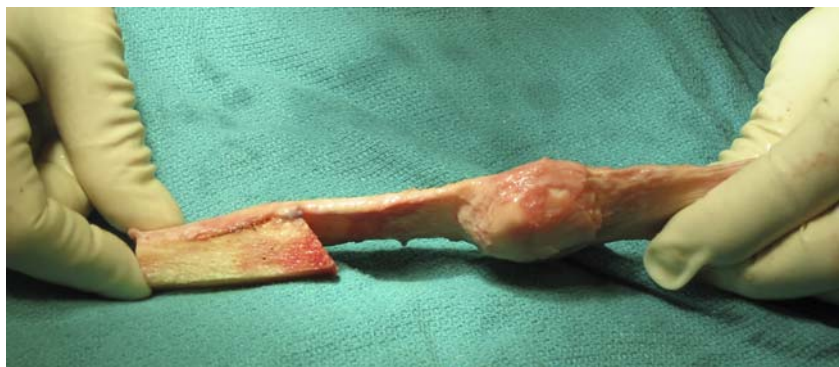

FIG. 14-A

Figs. 14-A through 14-D Finished cut of the tibial allograft segment with a proximal dovetail cut. **Fig. 14-A** Lateral view.

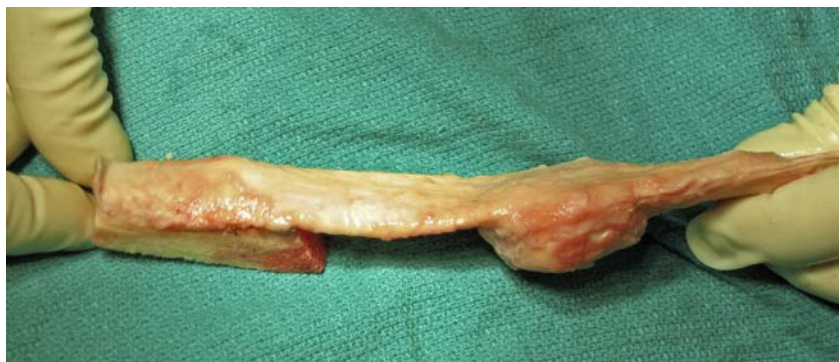

FIG. 14-B

Oblique view.

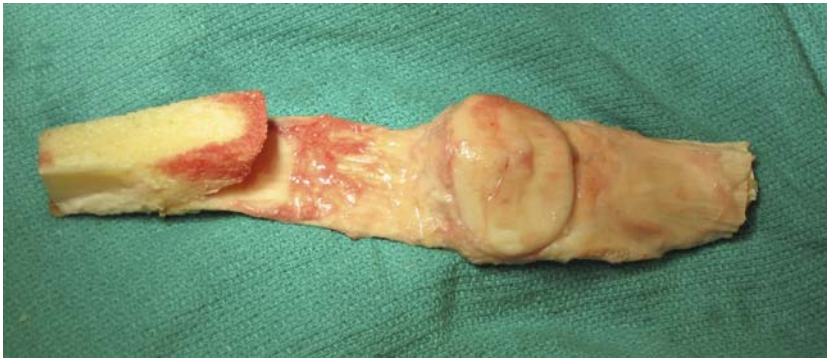


FIG. 14-C

Fig. 14-C Posterior aspect.

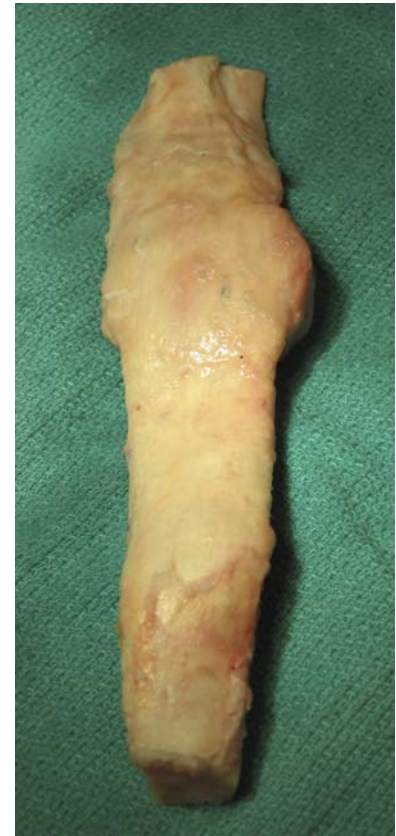

FIG. 14-D

Fig. 14-D Anterior aspect.

proximately 6 to 8 cm from the tibial articular surface of the allograft to the distal cut. The width of the block is 2 cm, and the depth is 2 cm (Fig. 11). We cut on the conservative side and make the cuts slightly larger if necessary, as these may be trimmed or downsized as needed. With use of a small thin microsagittal saw, the allograft block is harvested from the allograft tibia (Fig. 12), with careful attention so as not to damage the allograft patellar tendon (Fig. 13). The proximal bevel or “dovetail” on the allograft bone block is not created during this part of the harvest, as it is simpler

to perform once the graft has been removed from the allograft tibia.

Once the allograft bone block has been carefully removed from the allograft tibia, we next prepare the bevel, or dovetail, on the proximal aspect of the removed bone block (Fig. 12). This serves two purposes. The first is to lock into the host native tibial trough and avoid graft escape. The second is to allow a press-fit of the graft into the native tibia. Using a marking pen (Fig. 13), we draw an angle of 30° to 40° (from the perpendicular of the graft) as a bevel and cut it carefully with the thin

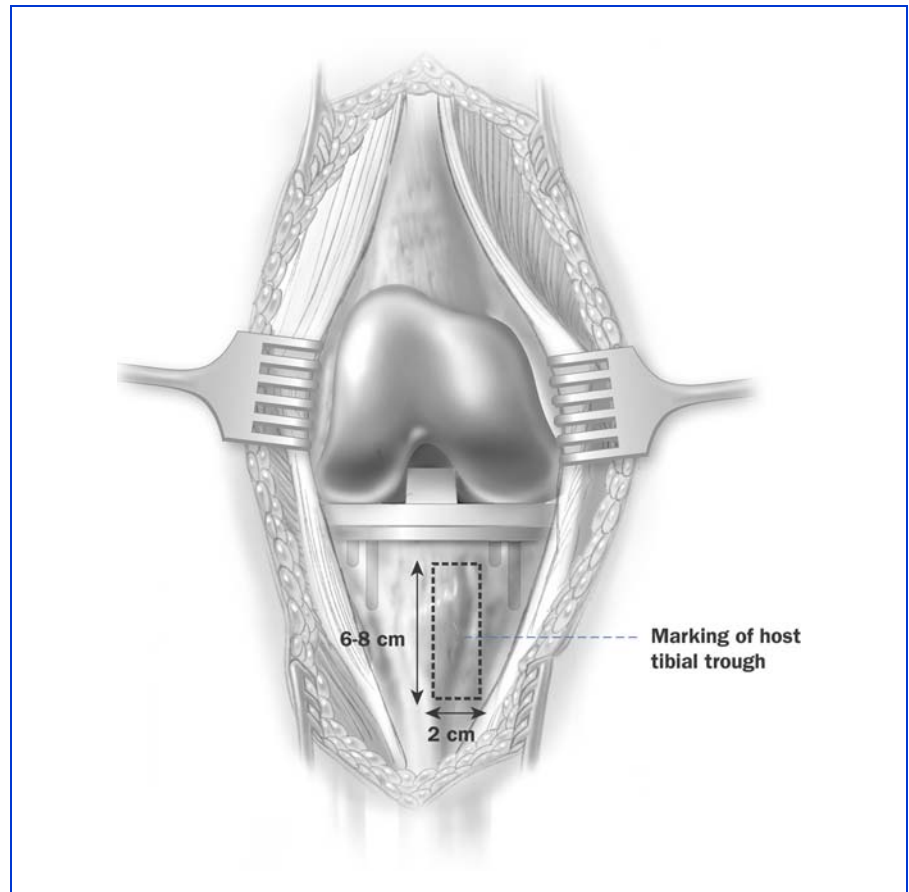
saw blade. The length of the bevel is approximately 20 to 25 mm (Figs. 14-A through 14-D).

Two number-2 nonabsorbable sutures are then placed in a running, locked fashion, as described by Krackow et al.⁹, along the medial and lateral aspects of the allograft quadriceps tendon, exiting out proximally. These sutures are kept long, and they are placed so that the assistant can apply tension and pull the allograft tightly proximally once it has been secured into the prepared tibial bed.

The graft and the proximal two sutures are then placed care-

CRITICAL CONCEPTS**INDICATIONS:**

- Disruption of the extensor mechanism (extensor lag) that is not amenable to or has failed a primary repair
- Patellar tendon rupture, avulsion, or prior excision
- Quadriceps tendon rupture, avulsion, or prior excision
- Patellar fragmentation or nonreconstructible patellar fracture
- Severe heterotopic ossification of the extensor mechanism
- Previous patellectomy with a total knee arthroplasty and symptomatic extensor lag
- Severe patella infera and arthrofibrosis of the extensor mechanism
- Conversion of previous knee arthrodesis to a total knee replacement with a fibrosed or deficient extensor mechanism

continued**FIG. 15**

The host proximal tibial trough is marked. Careful attention to the location of this trough in the region of the tibial tubercle or slightly medial to it will allow for improved patellar tracking.

fully in a basin on the back table, and attention is turned to the preparation of the proximal part of the host tibia.

Preparation of the Host Proximal Tibial Trough

Using a marking pen, we mark out the host proximal tibial trough (Fig. 15). We typically attempt to place the allograft tibial tubercle in a position that is close to, or slightly medial to, the position of the native tibial tubercle. In addition, we attempt to leave at least 15 mm of host bone intact below the tibial component

anteriorly to resist proximal migration or escape of the graft, although this 15 mm of bone is not always possible in the revision setting with associated bone loss. The rectangular tibial trough is then marked out for a length of 5 cm and a width of just less than 2 cm and a depth of 2 cm. Proximally, the host bone is beveled (Fig. 16) to accept a press-fit of the beveled, or dovetailed, allograft bone block (Fig. 17). This bevel in the host bone should be created with dimensions slightly smaller than the allograft bone block, in order to allow a press-

fit (Fig. 18). Two or three 18-gauge stainless steel wires are then placed through drill-holes in the tibia from medial to lateral (Fig. 19). These wires must pass deep to the tibial trough. If a stemmed tibial component is being used, it is easier to drill and place these wires prior to inserting the stemmed component. The allograft extensor mechanism is then inserted into the host tibial trough and is gently press-fit with a bone tamp or punch, in an “up and in” fashion, in order to lock the dovetail in place. The wires are then twisted,

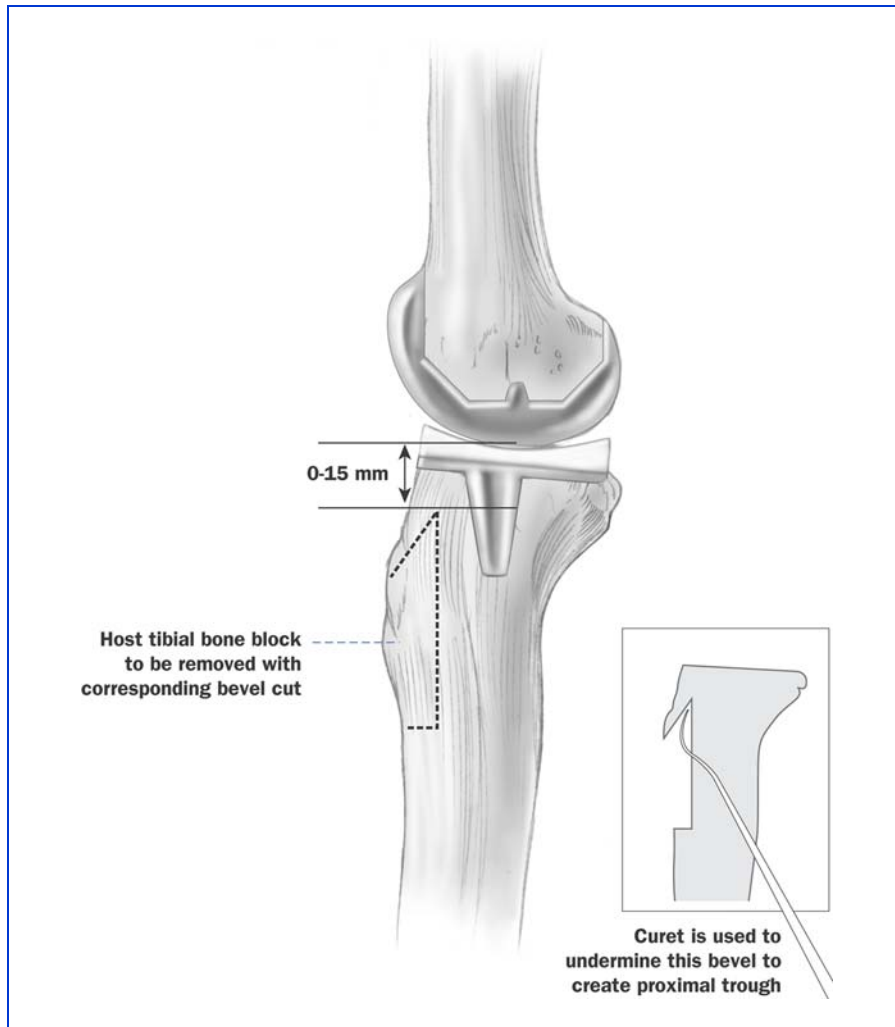


FIG. 16

The proximal host tibial trough is also beveled under to allow for a locking fit of the allograft tibial block. A small curet is useful to complete this bevel.

tightened, cut, and bent over against bone to avoid irritation to the soft tissues (Fig. 20). Alternatively, a small-fragment cortical screw and washer may be added to the fixation at the surgeon's preference. This creates a drill-hole in the allograft, and we prefer to avoid this stress-riser, despite the added security of the screw fixation.

Once we have secured the allograft bone into the host tibia, attention is turned to the proxi-

mal quadriceps medial and lateral sleeves and retinaculum.

Preparation and Tensioning of the Host Distal Quadriceps

Similar to the retention sutures placed in the allograft quadriceps, the host distal quadriceps medial and lateral soft-tissue sleeves are prepared. We again use a number-2 nonabsorbable suture (FiberWire; Arthrex, Naples, Florida) and place a short running Krakow suture into both the me-

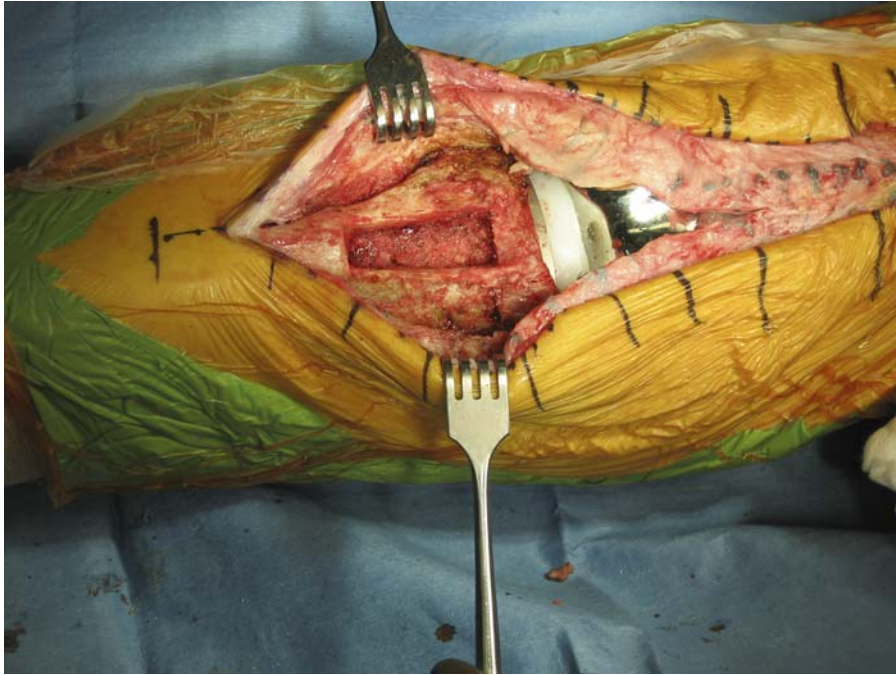
CRITICAL CONCEPTS | continued

CONTRAINDICATIONS:

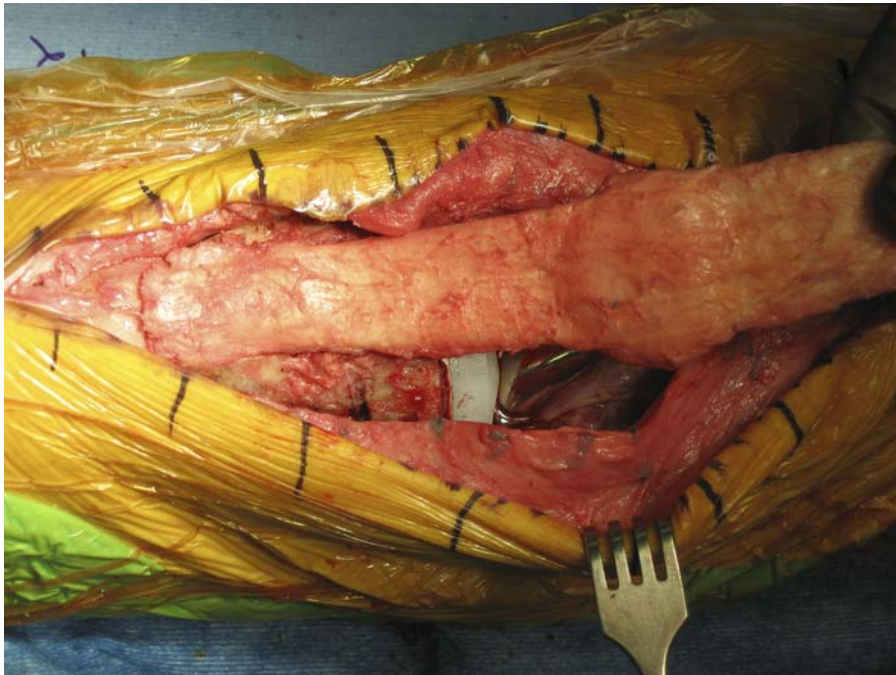
- Ongoing infection or concurrent infection of a total knee replacement at or near the operative site
- Reconstructible extensor mechanism with primary repair or local autogenous reinforcement tissue
- An unreliable, noncompliant patient who is unable to cooperate with postoperative rehabilitation

continued

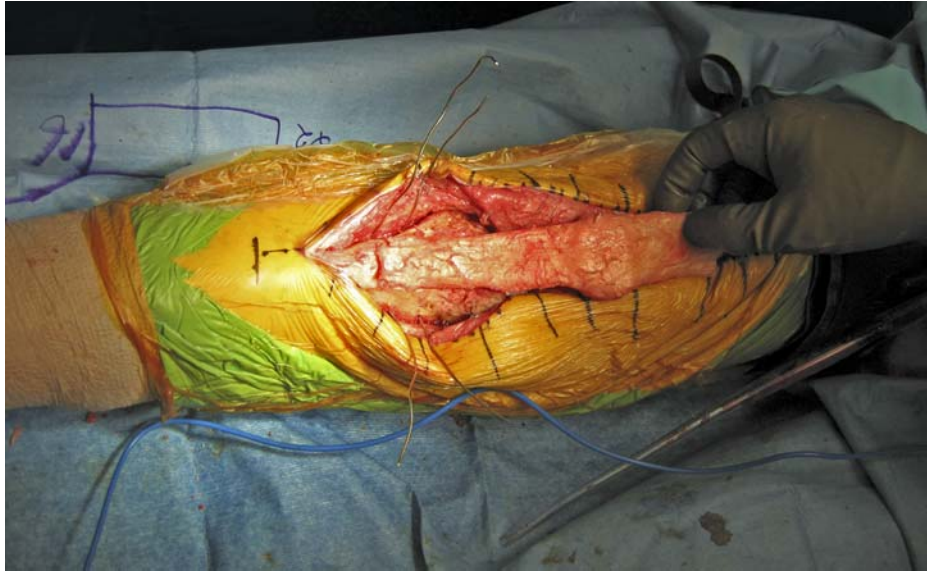
dial and lateral retinaculum in the distal quadriceps muscle-tendon junction. This allows a second assistant to “pull down” the host quadriceps mechanism (Fig. 21), effectively tensioning the distal host extensor mechanism (Fig. 22). The two previously placed allograft quadriceps sutures are pulled tightly with the knee in full extension (Figs. 23-A and 23-B). With use of a suture passer, these sutures are then pulled from distal to proximal, out and up through the more proximal host quadriceps. This pulls the allograft quadriceps up and under the host quadriceps, and simultaneously pulls or tensions the host quadriceps distally (Fig. 24). With this tension maintained, the allograft is then sutured in place beneath the host quadriceps with number-5 nonabsorbable suture, in a “vest-over-pants” fashion (see Fig. 24). Throughout this suture repair, the two assistants maintain tension on their respective retention sutures, in order to

**FIG. 17**

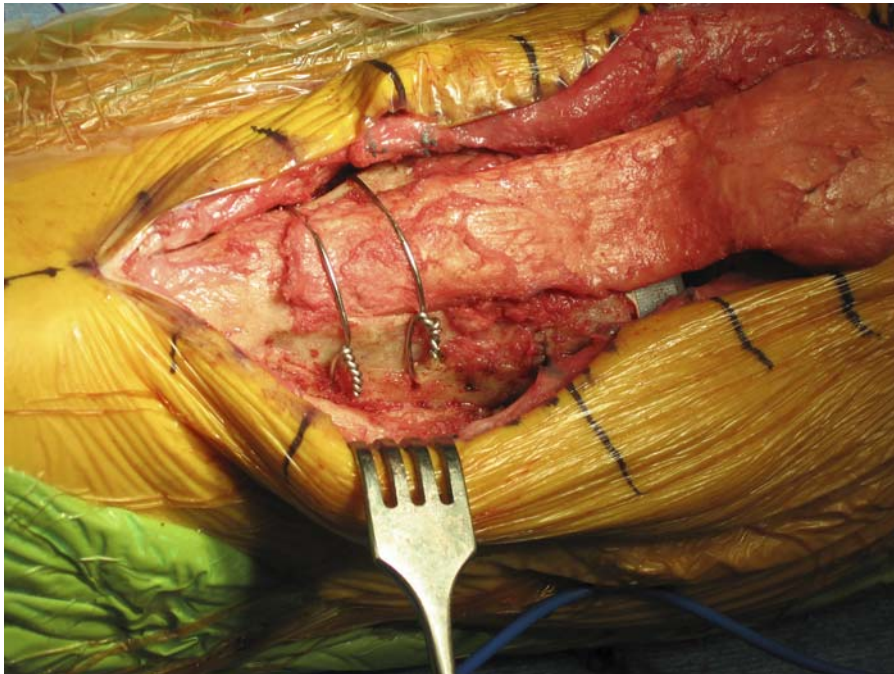
Completed anterior tibial trough, which is ready to accept the allograft extensor mechanism.

**FIG. 18**

The allograft tibial block is press-fit into the host tibial trough.

**FIG. 19**

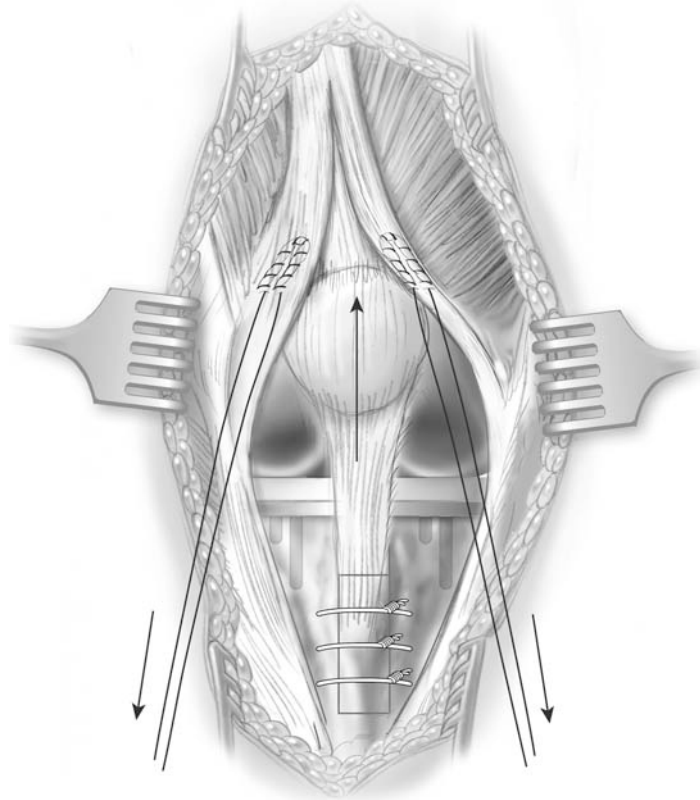
Fixation of the tibial allograft with stainless steel wires, which are drilled through the tibia, beneath the allograft.

**FIG. 20**

The wire fixation is secured after insertion of the allograft bone into the host tibia.

CRITICAL CONCEPTS | continued**PITFALLS:**

- A fresh-frozen, nonirradiated allograft specimen consisting of a quadriceps tendon, patella, patellar tendon, and tibial bone is required. It is preferable to have at least 5 cm of quadriceps tendon allograft for suture repair into the host quadriceps mechanism.
- We recommend use of a mid-line approach through the extensor mechanism anteriorly. Large medial and lateral flaps that provide excellent tissue for closure over the extensor mechanism allograft are developed. If there is native patella remaining, this is osteotomized transversely in line with the midline arthrotomy. The patellar remnant is then shelled out and removed.
- Component revision is often necessary. It is important that the knee be able to be passively brought to full extension with the trial implants in place, in order to ensure full extension is attainable postoperatively.
- It is important that the proximal aspect of the allograft tibial bone and the bone trough on the native tibia be dovetailed in order to lock, or press-fit, the allograft into the native tibia and resist proximal migration.
- When the allograft is sutured proximally into the native quadriceps, tension must be maintained on the allograft with the knee in full extension.

continued**FIG. 21**

Two running, locked Krakow sutures are placed into the medial and lateral host quadriceps retinaculum.

maintain tension with the knee in the extended position. Once the proximal aspect of the allograft is secured, the repair is continued along the medial and lateral sides. However, the repair is performed with the host retinaculum brought over the top of the allograft, in order to cover the allograft tissues as much as possible with the medial and lateral sleeves of the host retinaculum. We find that we are usually able to completely cover the allograft with these host sleeves that have been preserved, in addition to suturing the allograft

underneath these tissues (Fig. 25). Distally, the host tissues are closed over the wires and allograft bone block.

CLOSURE

We prefer to not flex the knee to “test” our repair once it is completed. This should be avoided in order to not stress the repair and attenuate the allograft host junction. The subcutaneous tissues are closed in routine fashion. The skin is closed with staples. If the skin over the distal incision is tenuous, nonabsorbable suture may be used.

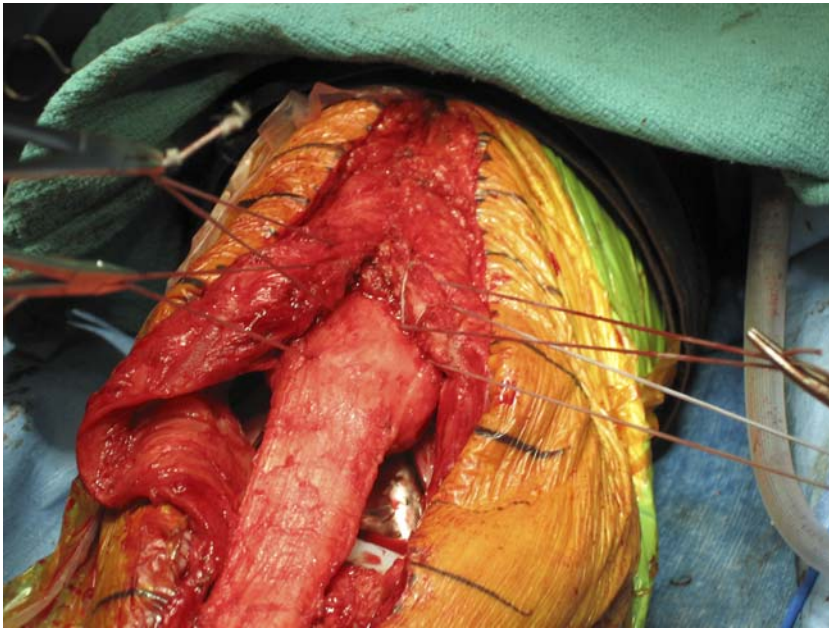


FIG. 22

These two sutures allow the host extensor mechanism to be tensioned by pulling distally.

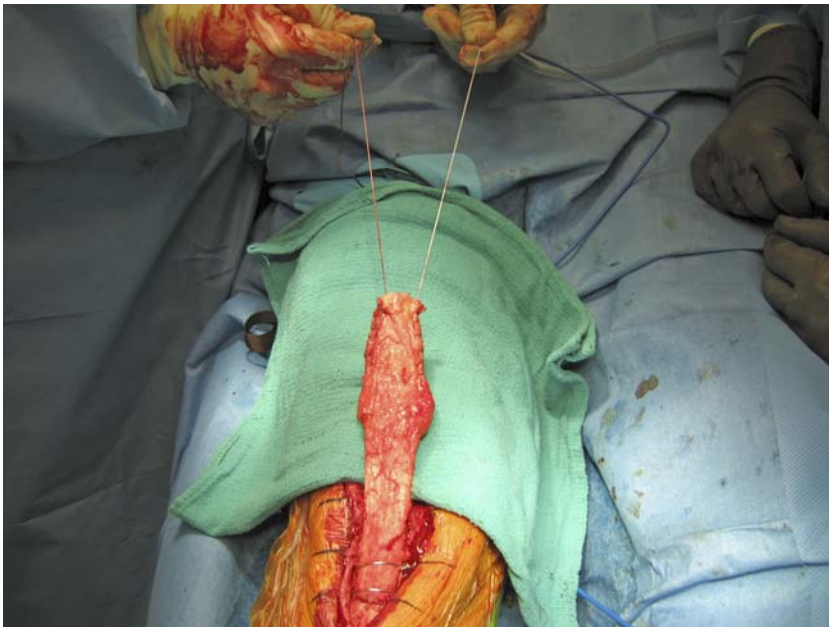


FIG. 23-A

Two sutures placed in the allograft quadriceps allow the allograft to be tensioned proximally.

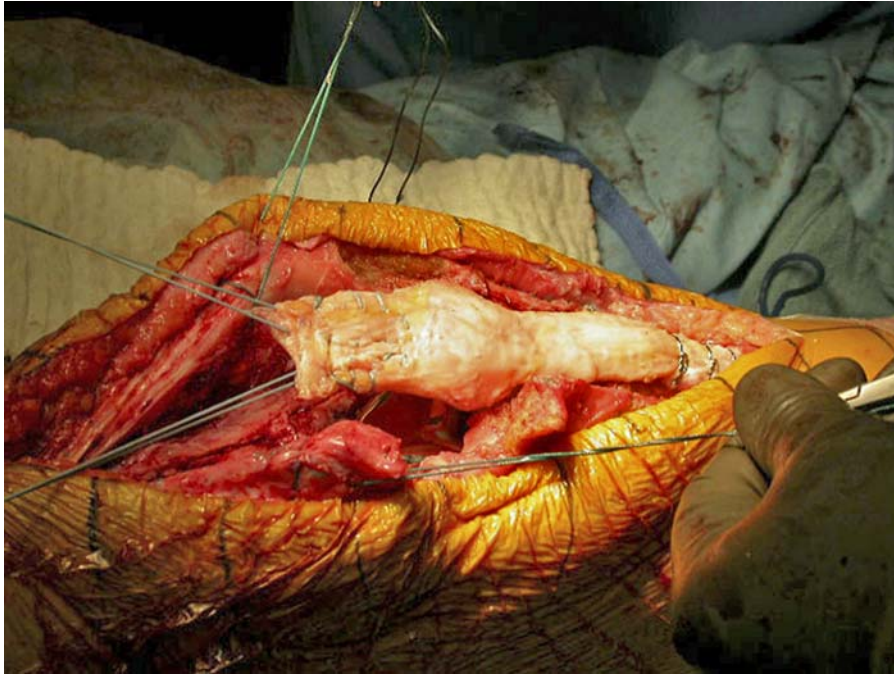
CRITICAL CONCEPTS | continued

- It is not desirable to have an overly long allograft quadriceps tendon. A segment that is too long will end up being sewn proximally into the rectus femoris muscle instead of into the host quadriceps tendon.
- The host retinaculum medial and lateral flaps should be sewn over the allograft as much as possible in order to cover the allograft.
- The knee should *not* be flexed intraoperatively to assess the flexion of the construct. The patient is managed with immobilization of the knee in full extension with touch-down weight-bearing for eight weeks, and then a directed physical therapy program is begun.
- The allograft patella is not resurfaced in order to avoid creating a stress-riser in it.

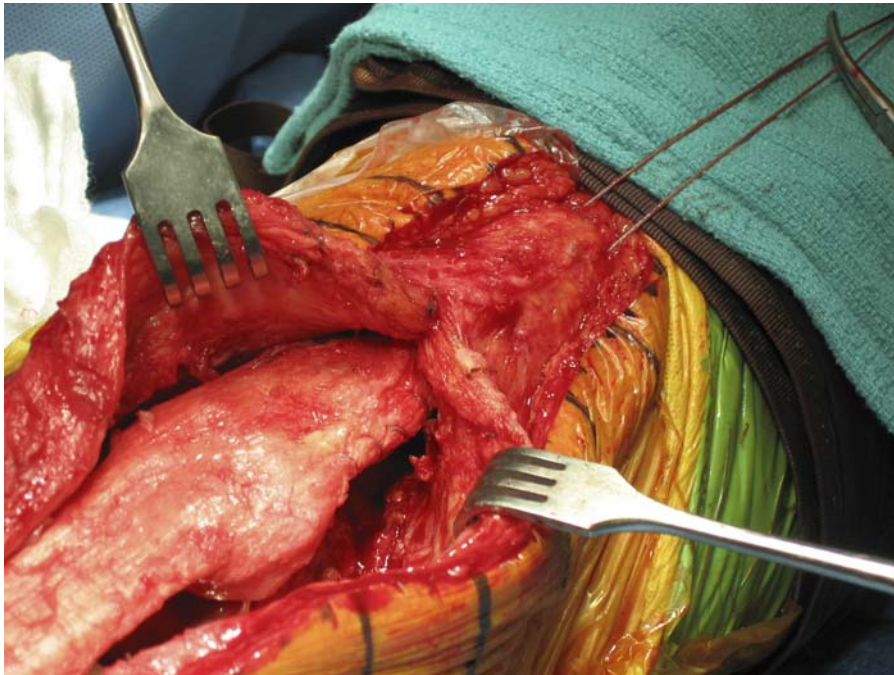
continued

POSTOPERATIVE CARE AND REHABILITATION

In the operating room at the completion of the procedure, the knee is placed in full extension. We prefer to use a knee immobilizer that is customized to the size and diameter of the extremity. This allows for complete immobilization of the knee in full extension and permits access to the wound postoperatively. A poor-fitting brace allows for flexion and movement, which should be avoided in the immediate postoperative period. Alternatively, a cylindrical fiberglass cast may be placed on the limb in the op-

**FIG. 23-B**

The host extensor mechanism and allograft are pulled by two separate assistants into an extension position.

**FIG. 24**

The sutures in the allograft quadriceps are pulled under the host quadriceps and out proximally through the host extensor mechanism.

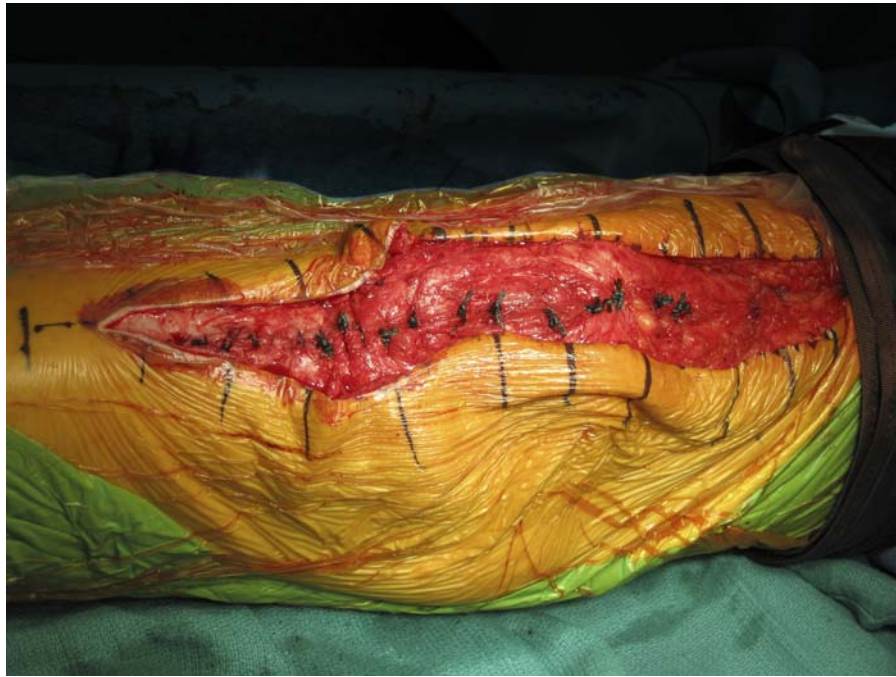

FIG. 25

The host medial and lateral sleeves of retinaculum, if preserved during the surgery, serve to cover the allograft completely, reducing the exposure of the allograft to the subcutaneous tissues.

erating room. The disadvantage of the cast is that it must be removed if there are concerns about the wound and in order to change the dressing postoperatively. In a patient with borderline compliance, this is the safest form of immobilization, but it is often poorly tolerated.

Postoperative physical therapy follows a protocol that we developed for this procedure. Patients are maintained with the knee in full extension for eight weeks after surgery. During this period, we allow touch-down weight-bearing only. We have the patient avoid full weight-bearing in order to reduce the quadriceps force on the tibial tubercle and the allograft-host soft-tissue

repair. We do not allow any flexion during this eight-week period. We encourage isometric static quadriceps contractions. After eight weeks, 30° of active

flexion is permitted, under the supervision of a physical therapist, with the patient wearing a hinged knee brace with a lock-out against further flexion. Simi-

CRITICAL CONCEPTS | continued

AUTHOR UPDATE:

This technique has not been modified since the publication of our original study. We emphasize that success with this technique requires that several critical aspects be carefully followed. The midline incision and retention of host medial and lateral retinacular tissue is important. Removing the patellar remnant in this way ensures that medial and lateral flaps remain for closure, and it improves exposure. Tensioning the allograft tightly in full extension is necessary to help to reduce the risk of allograft attenuation and extensor lag. Closure of the medial and lateral flaps over the allograft as much as possible reduces the contact of the allograft with subcutaneous tissues and, we believe, reduces the risk of infection. We emphasize that we do not flex the repair once it is completed, as has been recommended by other authors.

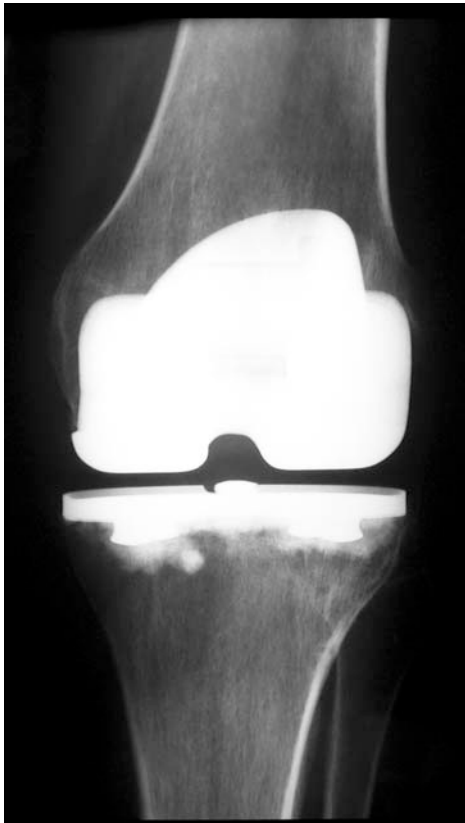

FIG. 26-A

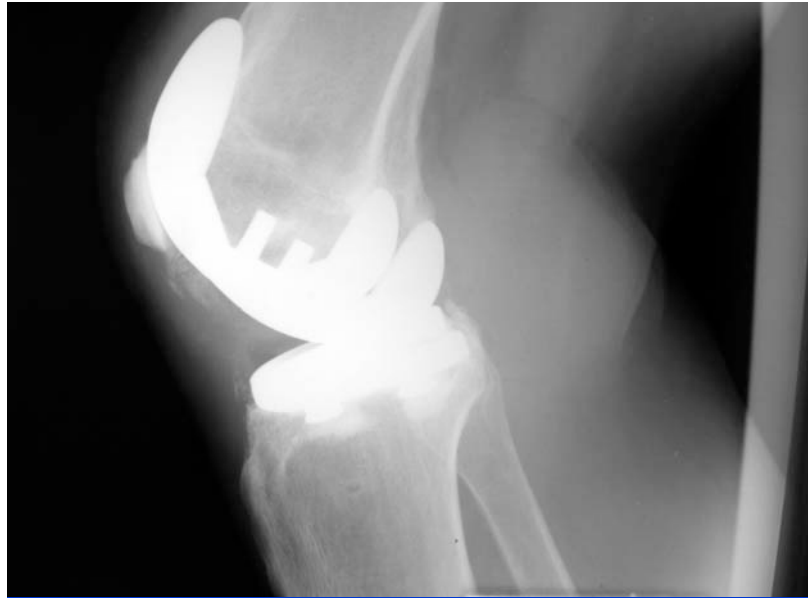

FIG. 26-B

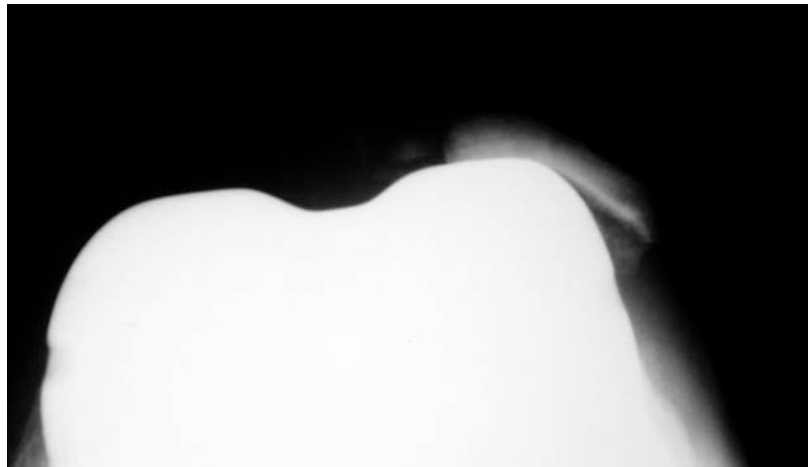


FIG. 26-C

Figs. 26-A, 26-B, and 26-C Preoperative radiographs showing a patient with a deficient extensor mechanism (patellar tendon attenuation) and component malrotation with lateral dislocation of the host extensor mechanism.

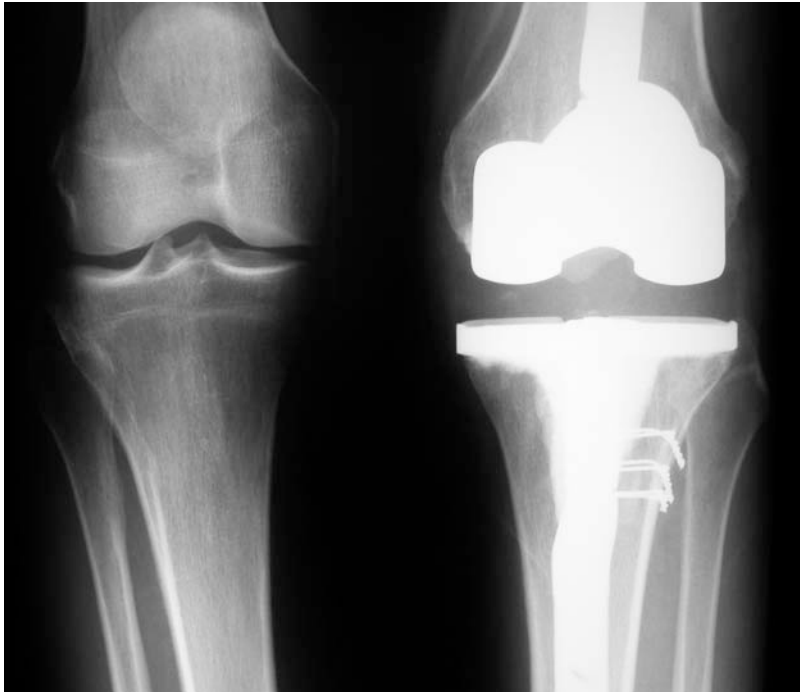

FIG. 26-D

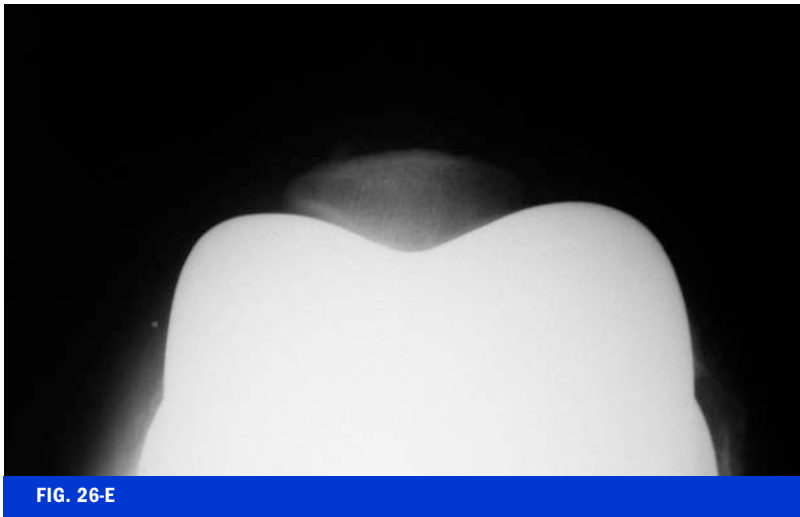


FIG. 26-E

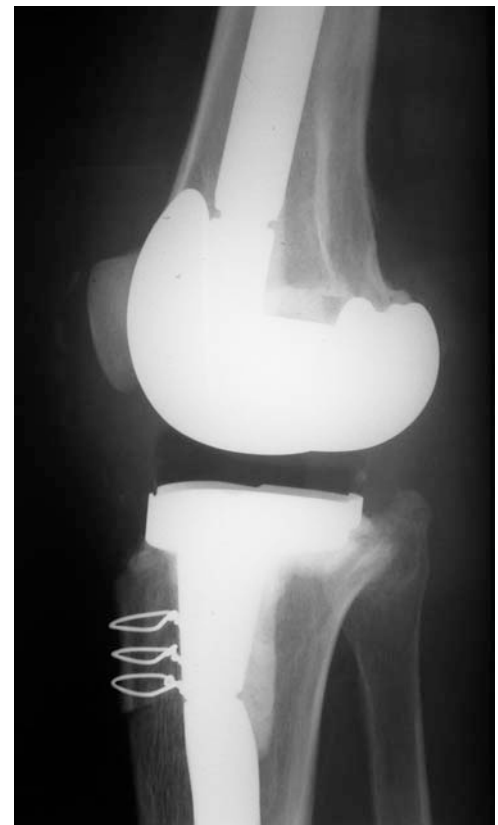

FIG. 26-F

Figs. 26-D, 26-E, and 26-F Radiographs made after component revision and reconstruction with an extensor mechanism allograft.

larly, at eight weeks, patients are advanced to weight-bearing as tolerated. During weight-bearing, we lock the brace in full extension. At twelve weeks, we allow further active flexion up to a maximum of 90°, and gentle quadriceps strengthening exercises are initiated. Passive flexion is not permitted in order to minimize the chance of graft failure and early attenuation. Patients are evaluated at six months and then on a yearly basis (Figs. 26-A through 26-F).

NOTE: The authors thank Regina M. Barden, RN, and Margaret Arp for their contribution to the preparation and clinical support for this study.

R. Stephen J. Burnett, MD, FRCS(C)
Department of Orthopaedic Surgery, Barnes
Jewish Hospital, Washington University, 660
South Euclid Avenue, Campus Box 8233,
St. Louis, MO 63110. E-mail address:
burnetts@msnotes.wustl.edu

Richard A. Berger, MD
Craig J. Della Valle, MD
Scott M. Sporer, MD
Joshua J. Jacobs, MD
Wayne G. Paprosky, MD

Aaron G. Rosenberg, MD
Rush University Medical Center, Midwest Ortho-
paedics, 1725 West Harrison Street, Suite 1063,
Chicago, IL 60612

In support of their research or preparation of this manuscript, one or more of the authors received grants or outside funding from Zimmer. In addition, one or more of the authors received payments or other benefits or a commitment or agreement to provide such benefits from a commercial entity (Zimmer). Also, a commercial entity (Zimmer) paid or directed, or agreed to pay or direct, benefits to a research fund, foundation, educational institution, or other charitable or non-profit organization with which the authors are affiliated or associated.

The line drawings in this article are the work of Jennifer Fairman (jfairman@fairmanstudios.com).

doi:10.2106/JBJS.E.00442

REFERENCES

1. Leopold SS, Greidanus N, Paprosky WG, Berger RA, Rosenberg AG. High rate of failure of allograft reconstruction of the extensor mechanism after total knee arthroplasty. *J Bone Joint Surg Am.* 1999; 81:1574-9.

2. Emerson RH Jr, Head WC, Malinin TI. Reconstruction of patellar tendon rupture after total knee arthroplasty with an extensor

mechanism allograft. *Clin Orthop Relat Res.* 1990;260:154-61.

3. Emerson RH Jr, Head WC, Malinin TI. Extensor mechanism reconstruction with an allograft after total knee arthroplasty. *Clin Orthop Relat Res.* 1994;303:79-85.

4. Nazarian DG, Booth RE Jr. Extensor mechanism allografts in total knee arthroplasty. *Clin Orthop Relat Res.* 1999;367:123-9.

5. Burnett RS, Fornasier VL, Haydon CM, Wehrli BM, Whitewood CN, Bourne RB. Retrieval of a well-functioning extensor mechanism allograft from a total knee arthroplasty. Clinical and histological findings. *J Bone Joint Surg Br.* 2004;86:986-90.

6. Burnett RS, Berger RA, Paprosky WG, Della Valle CJ, Jacobs JJ, Rosenberg AG. Extensor mechanism allograft reconstruction after total knee arthroplasty. A comparison of two techniques. *J Bone Joint Surg Am.* 2004; 86:2694-9.

7. Berger RA, Crossett LS, Jacobs JJ, Rubash HE. Malrotation causing patellofemoral complications after total knee arthroplasty. *Clin Orthop Relat Res.* 1998;356:144-53.

8. Crossett LS, Sinha RK, Sechriest VF, Rubash HE. Reconstruction of a ruptured patellar tendon with achilles tendon allograft following total knee arthroplasty. *J Bone Joint Surg Am.* 2002;84:1354-61.

9. Krackow KA, Thomas SC, Jones LC. Ligament-tendon fixation analysis of a new stitch and comparison with standard techniques. *Orthopedics.* 1988;11:909-17.