

THE JOURNAL OF BONE & JOINT SURGERY

# J B & J S

*This is an enhanced PDF from The Journal of Bone and Joint Surgery*

*The PDF of the article you requested follows this cover page.*

---

## **Achieving Stability and Lower-Limb Length in Total Hip Arthroplasty**

Keith R. Berend, Scott M. Sporer, Rafael J. Sierra, Andrew H. Glassman and Michael J. Morris  
*J Bone Joint Surg Am.* 2010;92:2737-2752.

---

**This information is current as of March 9, 2011**

### **Reprints and Permissions**

Click here to [order reprints or request permission](#) to use material from this article, or locate the article citation on [jbjs.org](http://jbjs.org) and click on the [Reprints and Permissions] link.

### **Publisher Information**

The Journal of Bone and Joint Surgery  
20 Pickering Street, Needham, MA 02492-3157  
[www.jbjs.org](http://www.jbjs.org)



---

SELECTED  
**INSTRUCTIONAL  
COURSE LECTURES**

---

**THE AMERICAN ACADEMY OF ORTHOPAEDIC SURGEONS**

**KENNETH A. EGOL**

EDITOR, VOL. 60

**COMMITTEE**

**KENNETH A. EGOL**

CHAIR

**FREDERICK M. AZAR**

**MARY I. O'CONNOR**

**MARK PAGNANO**

**PAUL TORNETTA III**

**EX-OFFICIO**

**DEMPSEY S. SPRINGFIELD**

DEPUTY EDITOR OF THE JOURNAL OF BONE AND JOINT SURGERY  
FOR INSTRUCTIONAL COURSE LECTURES

*Printed with permission of the American Academy of Orthopaedic Surgeons. This article, as well as other lectures presented at the Academy's Annual Meeting, will be available in February 2011 in Instructional Course Lectures, Volume 60. The complete volume can be ordered online at [www.aaos.org](http://www.aaos.org), or by calling 800-626-6726 (8 A.M.-5 P.M., Central time).*



AMERICAN ACADEMY OF  
ORTHOPAEDIC SURGEONS

# Achieving Stability and Lower-Limb Length in Total Hip Arthroplasty

By Keith R. Berend, MD, Scott M. Sporer, MD, Rafael J. Sierra, MD, Andrew H. Glassman, MD, MS, and Michael J. Morris, MD

*An Instructional Course Lecture, American Academy of Orthopaedic Surgeons*

Total hip arthroplasty is an exceptionally cost-effective and successful surgical intervention<sup>1,2</sup>. Dislocation, infection, osteolysis, and limb length inequality are among the most common complications affecting the long-term success of total hip arthroplasty<sup>2-8</sup>. Instability with dislocation is a complication that is costly to the patient, surgeon, and hospital<sup>9</sup>. The surgeon is frequently faced with the challenge of obtaining a stable hip at the cost of increasing the length of the lower extremity<sup>10</sup>. This Instructional Course Lecture addresses the common issues that surround the achievement of both stability and limb length equality with total hip arthroplasty. We review the preoperative patient education and factors associated

with stability and limb length, the effect and role of various surgical approaches, the surgical techniques, and the management of instability with and without limb length inequality.

## **Instability**

Dislocation rates are reported to be 0.3% to 10% after primary total hip arthroplasty and up to 28% after revision total hip arthroplasty. The incidence appears to be highest within the first year and rises at a rate of about 1% per five years to 7% at twenty-five years postoperatively<sup>11-21</sup>. A recent national database study revealed that instability/dislocation was the most common diagnosis resulting in revision total hip arthroplasty in the United States<sup>3</sup>. There

are patient-specific risk factors associated with instability, including female sex, increasing age, a diagnosis of osteonecrosis or femoral neck fracture, obesity, a high preoperative range of motion, and comorbidities<sup>5,13,15,22-33</sup>.

There are variables under the surgeon's direct control, including the surgical approach, component position and orientation, femoral head size, restoration of offset, preservation of soft-tissue integrity, limb lengths, and prosthetic impingement. Surgeon experience is a variable, and the risk of instability is inversely related to the case volume of the operating surgeon<sup>5,13,15,30-32,34,35</sup>.

## **Preoperative Evaluation**

Postoperative limb length inequality and hip instability are common causes of litigation<sup>36-38</sup>. A thorough preoperative discussion establishes realistic patient expectations, and a hierarchy of reconstruction goals should be outlined: first, well-fixed acetabular and femoral components; second, a dynamically stable construct; and third, equalization of limb lengths. The patient must understand and accept that lengthening of the lower limb may be

**Look for this and other related articles in *Instructional Course Lectures, Volume 60*, which will be published by the American Academy of Orthopaedic Surgeons in February 2011:**

- “The Evolution and Modern Use of Metal-on-Metal Bearings in Total Hip Arthroplasty,” by Mark Gonzalez, MD, MEng, Ryan Carr, MD, Sharon Walton, MD, and William M. Mihalko, MD, PhD

**Disclosure:** The authors did not receive any outside funding or grants in support of their research for or preparation of this work. One or more of the authors, or a member of his or her immediate family, received, in any one year, payments or other benefits or a commitment or agreement to provide such benefits from a commercial entity in excess of \$10,000 (Biomet and Zimmer) and less than \$10,000 (Innomed).

required in order to achieve the first two goals.

A complete medical and surgical history should be obtained. Previous surgery on either extremity can create limb length inequality that is not appreciated on a pelvic radiograph alone. Previous fracture, infection, physeal arrest, and various dysplasias may result in limb shortening. Abnormalities of the axial skeleton, such as prior spinal fusion, scoliosis, or neuromuscular disorders, or soft-tissue contractures associated with the hip or knee result in apparent limb length discrepancy. The combination of “true” and “apparent” limb lengths contribute to the patient’s subjective perception of limb length inequality (Figs. 1-A and 1-B)<sup>39</sup>.

#### Physical Examination

Observation of the patient’s gait identifies pelvic obliquity, weak abductors, and

dependence on assistive devices. The major muscles around the hip (abductors, adductors, and flexors) as well as the iliotibial band are assessed for contractures. The levels of the iliac crests are compared with the patient standing (Fig. 2), and the thoracic and lumbar spine is assessed for coronal or sagittal deformity.

True limb length is determined by measuring the actual length of the extremity clinically or radiographically. The apparent limb length is determined by adding the effects of pelvic obliquity and soft-tissue contractures. Clinically, true limb length is measured from the anterior superior iliac spine to the medial malleolus (Fig. 3). Accurate identification of the osseous and anatomic landmarks can be difficult, especially in obese patients. A compensatory, flexible scoliosis may develop in the presence of a true limb length inequality. The flexible deformities correct when a block

is placed under the shorter extremity or when the patient sits. A rigid coronal spinal deformity remains unchanged with these maneuvers.

#### Radiographic Assessment

Standing anteroposterior pelvic, anteroposterior femoral, and lateral femoral radiographs should be obtained. Because an arthritic hip frequently has an external rotation deformity, the anteroposterior pelvic and femoral radiographs should be made with the femur in 20° of internal rotation to avoid underestimation of femoral offset (Figs. 4-A and 4-B).

Preoperative radiographs provide an estimation of true limb length inequality. A line drawn between the inferior aspects of the obturator foramina, ischia, or radiographic “teardrops” on a supine anteroposterior view of the pelvis is used as the pelvic reference. The

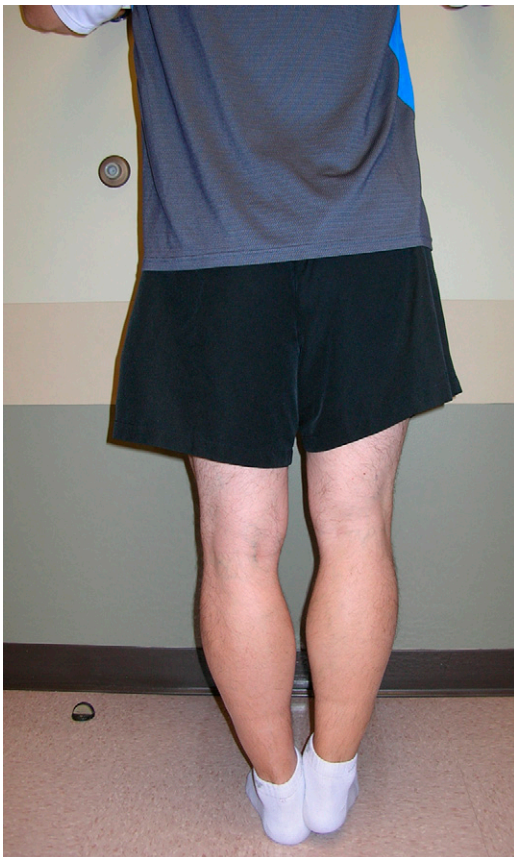

Fig. 1-A

**Fig. 1-A** There is a limb length discrepancy, with the right lower limb shorter than the left. Note the elevated heel of the right foot.

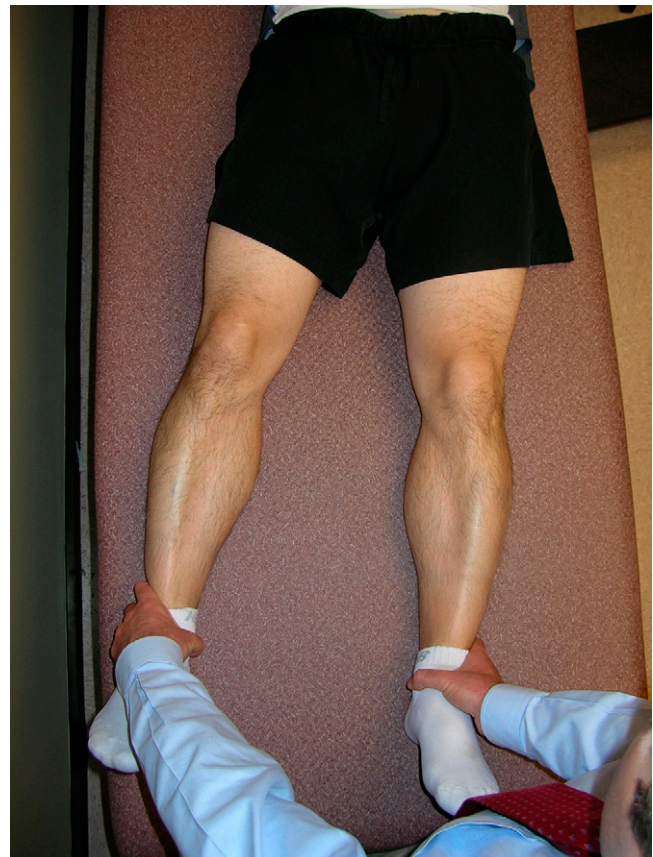

Fig. 1-B

**Fig. 1-B** Adduction contracture is present on the left, leading to the appearance of, but not true, limb length discrepancy.



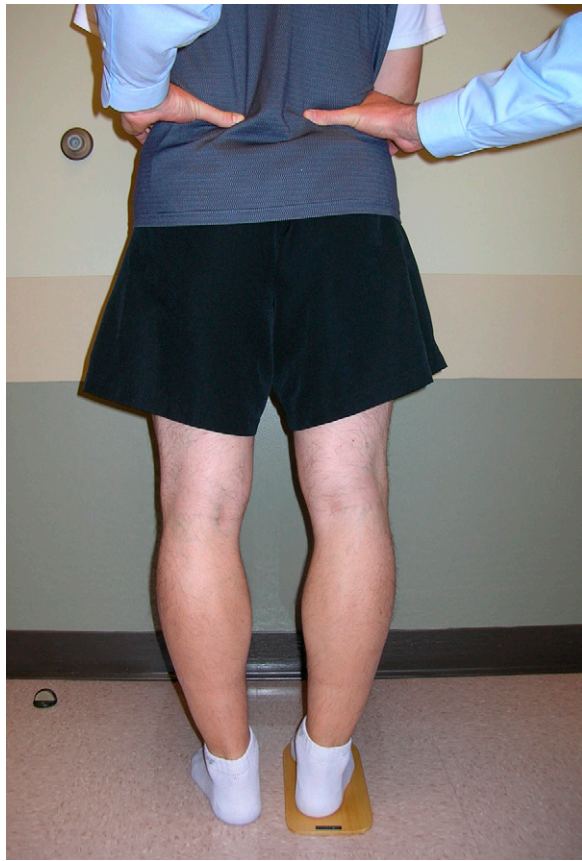

Fig. 2  
Standing evaluation of clinical limb length is performed by measuring the pelvic obliquity and limb length difference. The examiner's hands palpate the superior iliac crests, and blocks are added under the short lower limb until the pelvis is level. The block height needed to level the pelvis is the limb length difference.

distance between this line and a fixed point on the femur (the lesser or greater trochanter) can be compared with that of the contralateral hip. The difference between these two distances is the true limb length inequality (Fig. 5). This method is valid only if the limb lengths are equal below the chosen reference point and the two lower limbs are held in the same anatomic position.

Preoperative templating is essential to minimize limb length inequality, restore offset, and therefore minimize the possibility of instability (Fig. 6). First, the new center of rotation for the hip is determined by selecting the optimal position of the acetabular component. In general, the inferomedial aspect of the acetabular component is placed in close approximation to the radiographic tear-

drop such that the inferiormost aspect of the acetabular implant template is aligned with the radiographic teardrop in the vertical plane.

With femoral templating, the examiner should determine:

1. Prosthetic size—i.e., the fit and fill of the femur needed to achieve axial and rotational stability.
  2. Component offset. Extended-offset implants or a lateralized acetabular liner may be required to restore offset.
  3. Limb length. Limb lengthening (or, rarely, shortening) is planned on the basis of the preoperative radiographic evaluation as well as the clinical assessment of apparent limb length inequality.
- Not all patients with a true limb length inequality require lengthening.

Patients with a fixed adduction contracture or a pelvic obliquity may feel that the limb is excessively long if the true limb length is restored. A common reason for dislocation is the failure to adequately restore offset, which is the distance between the center of hip rotation and the center of the femoral canal<sup>40</sup>. Technically, templating can be performed on the contralateral, normal hip and changes in limb length or offset can be extrapolated to the hip that is to be operated on. Subsequently, femoral head-neck length and implant offset can be anticipated. Alternatively, templating of the hip that is to be operated on can allow immediate recognition of how much length or offset will be changed by anatomic placement of components, compared with the nonoperative side.

#### *Patient Expectations*

Preoperative discussions about limb length inequality and the possibility of hip dislocation are critical and should set realistic goals and reiterate the hierarchy of surgical priorities<sup>36</sup>. Patients must be aware that in some situations the lower limb must be lengthened to achieve component stability. Additionally, patients should be told that their lower limb will feel long immediately after the surgery and that this is a normal physiologic response following hip replacement. Patients who have a sense that the lower limb is longer preoperatively but actually have normal limb lengths, or those with a shortened extremity but the perception of equal limb lengths, are particularly at risk for perceiving that they have a discrepancy after surgery and should be appropriately warned preoperatively<sup>41</sup>.

#### **Advantages and Disadvantages of Surgical Approaches in Terms of Limb Length and Stability**

##### *Anterior Approaches*

The true anterior approaches expose the hip through the interval between the sartorius and tensor fascia femoris muscles, with several variations. The classic approach is the Smith-Petersen approach with either preservation or detachment of the direct head of the rectus femoris tendon. A variation of

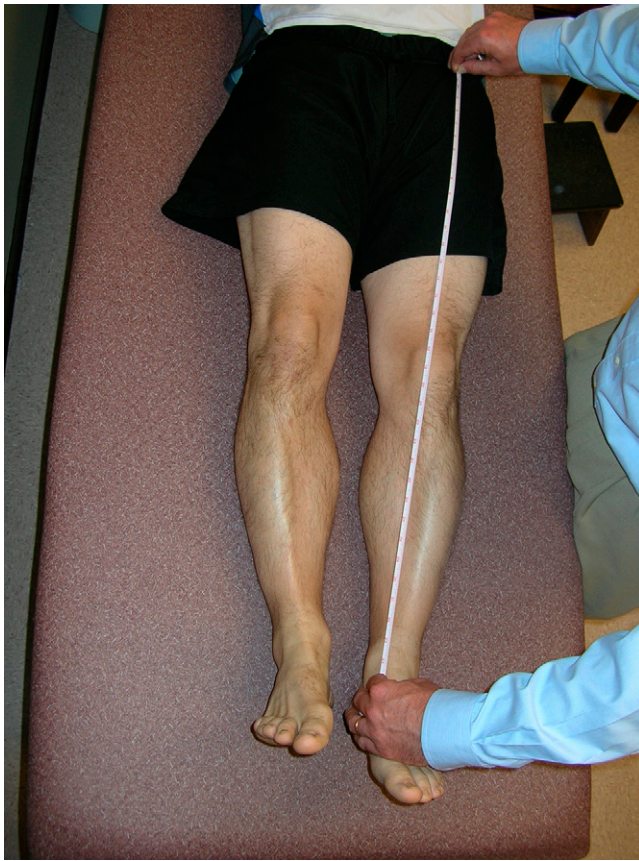

Fig. 3  
Supine evaluation of limb length inequality is performed by measuring the distance between the anterior superior iliac spine and the medial malleolus with a tape measure.

this approach, the Hueter approach (a fascial incision over the tensor fascia femoris), has gained interest because of its theoretic ability to provide protection to the lateral femoral cutaneous nerve, which is at risk with the classic Smith-Petersen approach<sup>42-44</sup>.

**Limb length:** A major advantage of the direct anterior approach is the ability to directly measure limb lengths because the patient is in the supine position and the true limb length can be measured at the ankle or heel. An intraoperative supine radiograph or fluoroscopy is helpful for the measurement of limb lengths and component position. Studies have shown an average mean limb length discrepancy of 3.9 mm with use of this approach<sup>43,44</sup>. This small amount of lengthening is well tolerated and accepted by the patient, making this approach one of the most accurate in terms of limb length reconstruction.

**Stability:** The direct anterior exposure is a true internervous plane between the sartorius (femoral nerve) and tensor fascia femoris (superior gluteal nerve). This approach minimizes soft-tissue damage about the hip and preserves the major abductor attachment. Only the anterior aspect of the capsule is excised. Advocates point out that no muscle detachment is necessary in order to deliver the femur anteriorly. The dislocation rate after a single-incision anterior approach ranges from 0.6% to 1.3%<sup>42-44</sup>.

**Disadvantages:** The approach is technically demanding and may or may not require the use of a specialized fracture table. There is a steep learning curve associated with the procedure<sup>42,45</sup>. The lateral femoral cutaneous nerve is always retracted, and the risk of injury to this nerve should be discussed with the patient preoperatively.

### Two-Incision Technique

The two-incision technique was described by Light and Keggi<sup>46</sup> and was popularized by Berger<sup>47,48</sup>. It is basically an anterior Smith-Petersen approach with an additional posterior smaller incision for placement of the femoral component.

**Limb length:** The advantages of this approach are similar to those of the direct anterior approach.

**Stability:** Excessive femoral anteversion is a risk because it is difficult to maintain anatomic version while inserting the femoral component through the small posterior incision. The reported dislocation rate after this procedure is relatively low (1.0%)<sup>47-50</sup>.

**Disadvantages:** The two-incision approach is not popular because it is technically difficult, has a steep learning curve, and has a high intraoperative complication rate. In addition, there may be injury to the abductor muscles<sup>49,51-53</sup>.

### Anterolateral, Direct Lateral, or Hardinge Approach

Direct lateral approaches include the Hardinge approach, in which the gluteus medius tendon is displaced with the vastus lateralis anteriorly and the hip is dislocated anteriorly<sup>54</sup>. Mallory et al. described a modified direct lateral approach, in which the anterior portion of the gluteus medius is dissected and displaced anteriorly with the vastus lateralis<sup>55</sup>.

**Limb length:** Some surgeons perform this approach with the patient in the supine position, and this may have an advantage in terms of obtaining equal limb lengths. The approaches that dislocate the hip anteriorly offer some additional protection against dislocation compared with posterolateral approaches<sup>56</sup>. Therefore, slight laxity in the hip to keep the lower limbs of equal length is acceptable.

**Stability:** The cumulative ten-year rate of dislocation has been reported to be 3.1% after anterolateral approaches but 6.9% after posterolateral approaches<sup>48,57,58</sup>.

**Disadvantages:** This approach violates the abductor mechanism and is sometimes associated with a postopera-

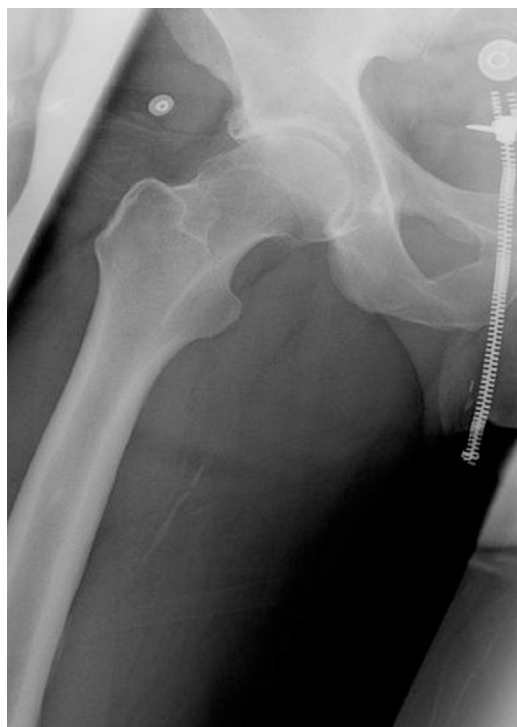

Fig. 4-A

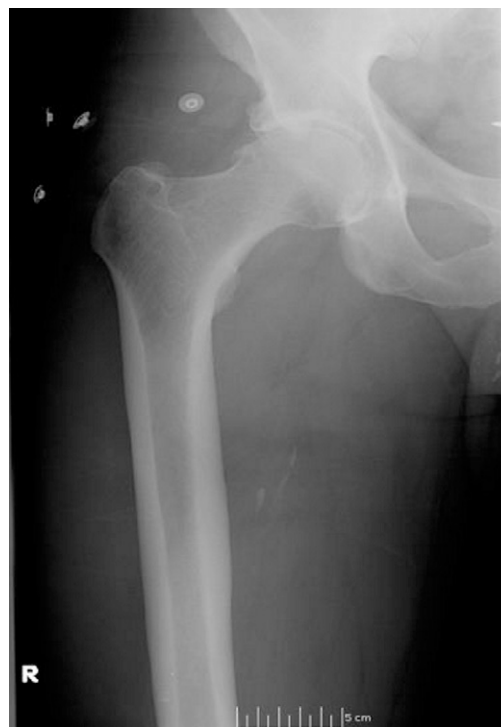

Fig. 4-B

**Fig. 4-A** Anteroposterior radiograph of a right femur in an externally rotated position. A false femoral offset is seen. **Fig. 4-B** Anteroposterior radiograph of the same right femur with the hip in 20° of internal rotation. Note the marked femoral offset.

tive limb. Damage to the superior gluteal nerve can occur and leads to denervation of the muscles that it innervates<sup>59</sup>. Heterotopic ossification is more common than it is with other approaches, and this heterotopic bone has required removal in 1% of patients<sup>58</sup>, a rate that is higher than that associated with other approaches.

#### Posterolateral Approach

The posterolateral approach is the most extensile of all approaches, allowing complete exposure of the femur and acetabulum. It is the most commonly used approach in North America, primarily because it avoids damage to the abductor muscles<sup>50,60,61</sup>. Small-incision techniques have gained favor in recent years<sup>61</sup>. The debate over the clinical benefit and the effect on limb length and stability of this approach is beyond the scope of this report<sup>61,62</sup>.

**Limb length:** When the posterolateral approach is used, the limb lengths are difficult to accurately measure with physical examination or radiographs, so some other means of determining limb length is necessary. Because of concerns

about postoperative dislocation, it is not uncommon for the extremity to be overlengthened during the hip arthroplasty with this approach<sup>63</sup>.

**Stability:** The risk of dislocation associated with the posterior approach is higher than that found with transtrochanteric, anterolateral, and anterior-based approaches<sup>13,16,21,64</sup>. In a study of over 21,000 primary total hip arthroplasties, Berry et al. reported dislocation rates, at the time of a ten-year follow-up, of 3.1%, 3.4%, and 6.9% for the anterolateral, transtrochanteric, and posterolateral approaches, respectively<sup>13</sup>. A meta-analysis by Masonis and Bourne suggested that the dislocation rate associated with the posterior approach is sixfold higher than that observed with a direct lateral approach<sup>64</sup>. Proper repair of the capsule and short external rotators after a posterior approach reduces the incidence of dislocation<sup>60,64-69</sup>. Furthermore, Kim et al. advocated preserving the external rotators during the posterior approach, a technique that resulted in zero dislocations<sup>70</sup>.

**Disadvantages:** The risk of injury to the sciatic nerve with the posterior approach is reported to be 0.6%<sup>71,72</sup>. However, as a result of the proximity of the nerve with this approach, the risk of sciatic nerve injury is higher than that associated with all other surgical approaches<sup>59,70,73</sup>.

#### Surgical Technique

##### Implant Positioning: Acetabular Component

Implant malposition is a major contributor to instability and dislocation. Correct implant position decreases wear and reduces the risk of dislocation, but other factors play a role in hip stability<sup>74,75</sup>. Multiple investigators have attempted to define a safe zone of acetabular component anteversion and inclination, or abduction. It is widely believed that the acetabular component should be placed in approximately 45° (40° to 60°) of abduction and should be anteverted 15° to 20° (Fig. 7)<sup>18</sup>. The safe zone is 15° ± 10° of anteversion and 40° ± 10° of abduction<sup>18</sup>. Total hip arthroplasty components that dislocate



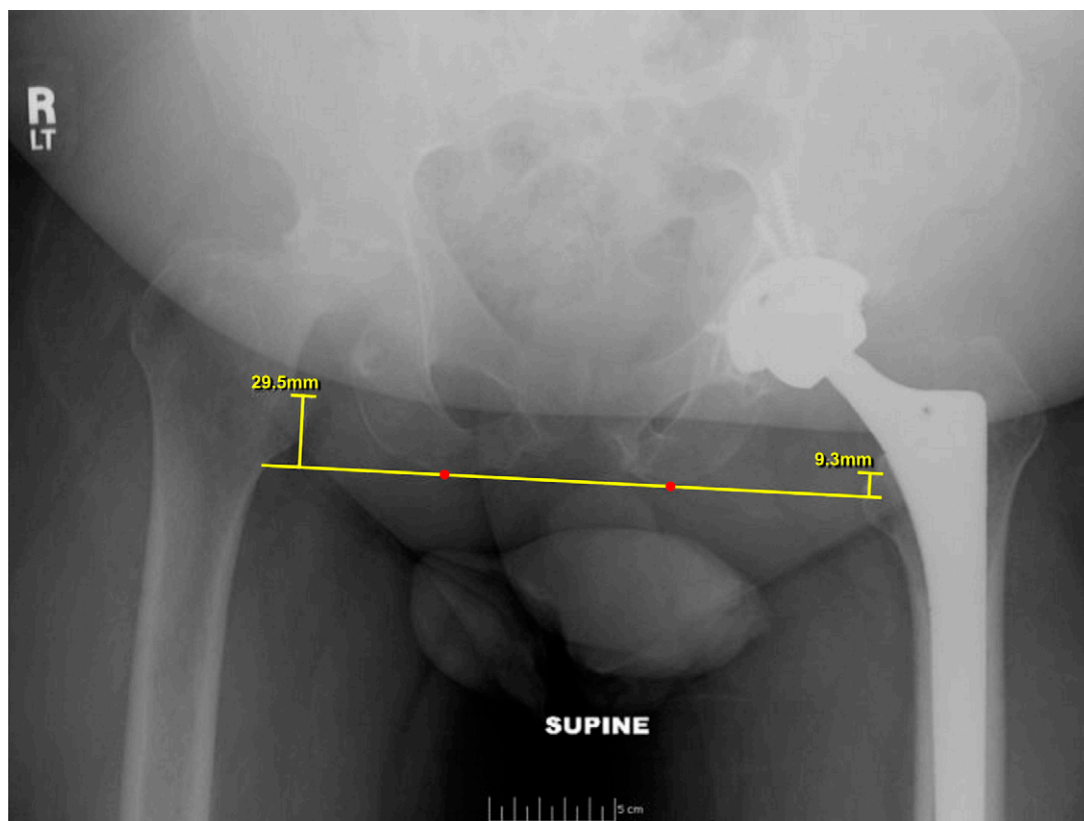


Fig. 5

Preoperative anteroposterior pelvic radiograph made with the patient supine shows severe erosive arthritis of the right hip. A line is drawn at the most inferior portions of the ischia, providing the pelvic reference line. A perpendicular line is drawn bilaterally from the transischial line to the superior aspect of the lesser trochanter to determine the limb length difference. The patient has a preoperative limb length discrepancy of 2.0 cm.

anteriorly have mean anteversion and abduction angles that are greater than the safe zone, while those that dislocate posteriorly have mean anteversion and abduction angles that are less than the safe zone<sup>76</sup>. The position of the acetabular cup is not the only factor affecting instability and dislocation. Hassan et al. reported that 42% of total hip prostheses in which the acetabular cup was positioned outside the safe zone did not dislocate<sup>77</sup>. Rittmeister and Callitsis noted that, while almost 20% of acetabular cups were positioned outside the safe zone in their study, there was no increase in dislocations in that group<sup>78</sup>.

#### **Implant Positioning: Reference Landmarks**

Landmarks are useful in assisting with positioning of the acetabular component. McCollum and Gray investigated multiple external reference points for

acetabular component positioning and found that significant changes in pelvic position and orientation occur when the patient is in the lateral decubitus position<sup>79</sup>. Care must be taken to evaluate the effects of body position when using external cues for orientation of the acetabular component during surgery.

Fixed anatomic landmarks, in contrast to external aiming devices, are independent of patient positioning. Useful landmarks include the transverse acetabular sulcus, the acetabular sulcus on the ischium, the most lateral prominence of the superior pubic rami (pubis), and the most superior aspect of the acetabulum<sup>80,81</sup>. These landmarks define a plane of orientation for acetabular component positioning that provides stability within a safe arc of motion<sup>81</sup>. An average cup position of 44° of abduction and 13° of anteversion can be achieved with use of these landmarks<sup>81</sup>.

Computer navigation, or computer-assisted orthopaedic surgery (CAOS), has been proposed as a method for accurately determining correct acetabular component positioning. CAOS reduces outliers but is not totally reliable<sup>82-84</sup>. The cost and technical aspects of CAOS currently prohibit widespread use.

#### **Implant Positioning: Femoral Component**

The positioning of the femoral component affects limb length, offset, abductor tension, and stability. All other things being equal, a distally placed femoral stem will result in a limb that is shorter than that resulting from a more proximally placed stem. The level of the femoral component has an equally important, albeit less obvious, effect on femoral offset. Femoral offset is defined as the distance from the center of rotation of the femoral head to a line



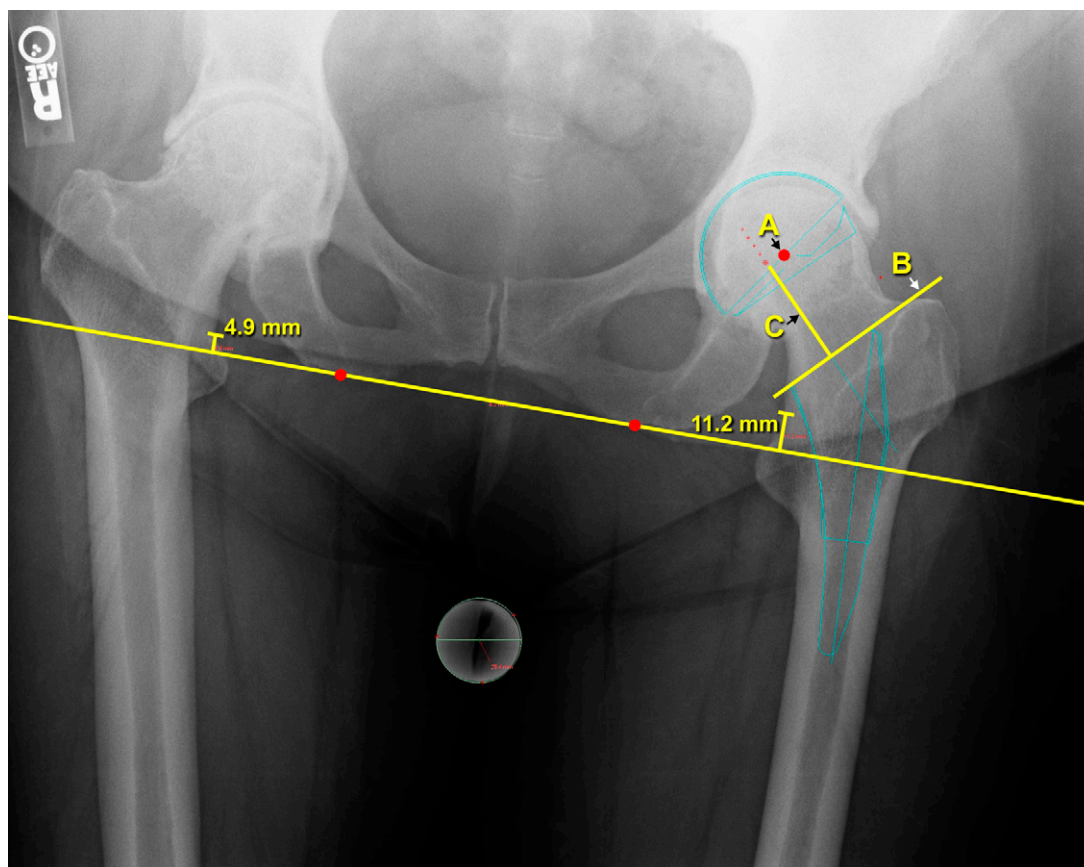


Fig. 6

Preoperative templating can be performed with use of computerized radiology software. The new, anatomic center of rotation is templated (A), and the acetabular implant size is determined with use of the hip that is not being operated on. The appropriate femoral stem size and position are templated. The corresponding neck cut (B), prosthetic neck length (C), and limb length difference are noted.

bisecting the long axis of the femur. Reconstruction of the femoral offset is important for restoring the biomechanics of the hip and specifically the abductor lever arm. Proper restoration of offset enhances hip motion and reduces the risk of dislocation<sup>85</sup>. A high femoral neck resection can be combined with a short neck length to yield the same limb length as provided by a low femoral neck resection combined with a long modular head. However, the first combination yields less femoral offset and may be appropriate in the presence of coxa valga. The second combination yields greater offset and is better for hips with coxa vara. Varus or valgus malpositioning of the stem will increase or decrease offset and should be avoided. Rotational alignment of the stem to the appropriate femoral anteversion influ-

ences the amount of hip motion that is possible before impingement occurs as well as abductor tension. Herrlin et al. noted that femoral anteversion was significantly reduced in hips that dislocated after total hip arthroplasty<sup>86</sup>. The ideal femoral anteversion is 15° to 20° in an osteoarthritic hip with otherwise normal anatomy. Acetabular deformity or deficiency may dictate less than ideal orientation of the acetabular component. To compensate for this, the femoral component may need to be placed in greater or less anteversion. In recognition of this possibility, the concept of combined acetabular and femoral component anteversion has been introduced. Using a mathematical model, Widmer and Zurfluh determined that the acetabular component should be in 40° to 45° of inclination

(abduction) and 20° to 28° of anteversion (forward flexion)<sup>87</sup>. This is combined with femoral anteversion such that the femoral anteversion multiplied by 0.7, plus the cup anteversion, should equal 37° in order to provide the greatest range of motion without impingement. Modular femoral components of various designs that allow adjustments in offset and anteversion without limb lengthening are now available from various manufacturers<sup>4,88</sup>.

There are some general rules of thumb for placing a femoral stem in the correct position. The proximal-distal position of the femoral stem is assessed in relation to the greater and lesser trochanters. Alternatively, the center of the femoral head in relation to the tip of the greater trochanter is noted. Additionally, the piriformis fossa can serve as a land-

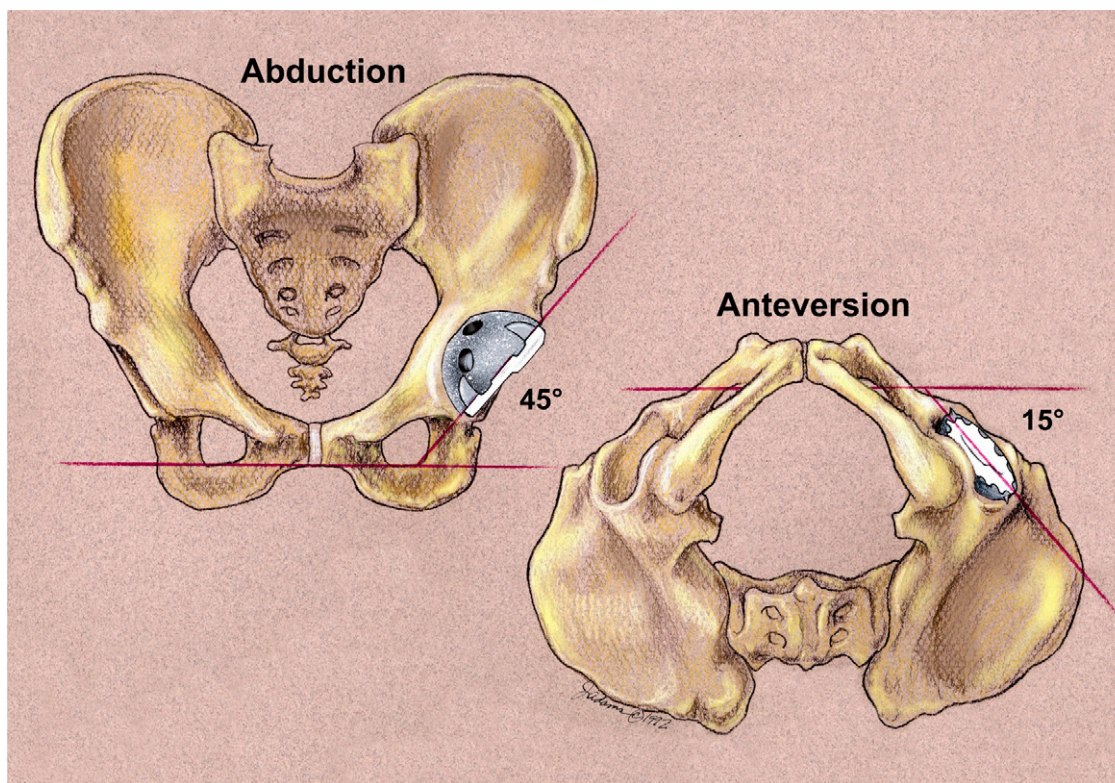


Fig. 7

The so-called safe zone for orientation of the acetabular component. (Printed with permission of Joint Implant Surgeons, Inc., New Albany, Ohio.)

mark for femoral neck resection. When the posterior approach is used, the templated neck resection can be easily reproduced by measuring the level of resection from the top of the lesser trochanter. This landmark is easily visualized on preoperative radiographs and intraoperatively, even through limited exposures. Woolson et al. described using the templated femoral neck and head segment as a guide for placing the femoral stem<sup>89</sup>. By placing the femoral stem at that osteotomy level, they achieved an appropriate limb length in 97% of cases.

#### *Soft-Tissue Balancing*

By restoring femoral offset and limb length, proper balancing of the soft tissues around the hip minimizes postoperative instability, pain, and limp<sup>90,91</sup>. Inadequate restoration of femoral offset increases the risk of dislocation by decreasing soft-tissue tension<sup>91</sup>. Excessive limb lengthening can result when intraoperative instability due to inadequate offset is inappropriately addressed

by increasing the neck length in an attempt to restore soft-tissue tension<sup>38</sup>. As mentioned, the combination of these factors is critical for understanding prosthetic hip stability<sup>19</sup>.

Better wear performance of the implants has been observed after femoral head medialization and femoral shaft lateralization. In addition, restoration of offset is associated with better functional and clinical results<sup>85,92,93</sup>. Bourne and Rorabeck reviewed the available methods employed to restore offset<sup>90</sup>. The most common approach is the use of a lateralized (“high-offset”) femoral stem (Fig. 8). Another option is to use a lateralized acetabular liner. However, such liners decrease the abductor moment arm, increase the joint reactive force, and result in accelerated polyethylene wear<sup>90</sup>. A lower-level neck resection and more distal femoral stem placement combined with a longer neck segment can lateralize the femoral shaft without lengthening the limb. However, longer heads with skirts should be

avoided because they decrease motion as a result of impingement.

Concerns have been raised that excessive femoral lateralization may increase the incidence of thigh pain and trochanteric bursitis or place undue strains on the bone-cement or biologic interfaces, leading to loosening. This latter concern has been refuted, and data show that, when indicated, the use of a lateralized stem improves the accuracy of hip soft-tissue reconstruction and does not increase thigh pain, trochanteric pain, or loosening<sup>96</sup>. In fact, proper soft-tissue balancing, obtained with a lateralized stem, is associated with less thigh and trochanteric pain<sup>94</sup>. However, over-lateralization should be avoided. Incavo et al. demonstrated that excessive lateralization led to a 15% incidence of trochanteric pain<sup>95</sup>. The value of intraoperative tests of soft-tissue balance such as the “shuck” or “drop-kick” test is highly dependent on the surgical approach, anesthetic technique, and surgeon experience<sup>90</sup>. These tests, however,



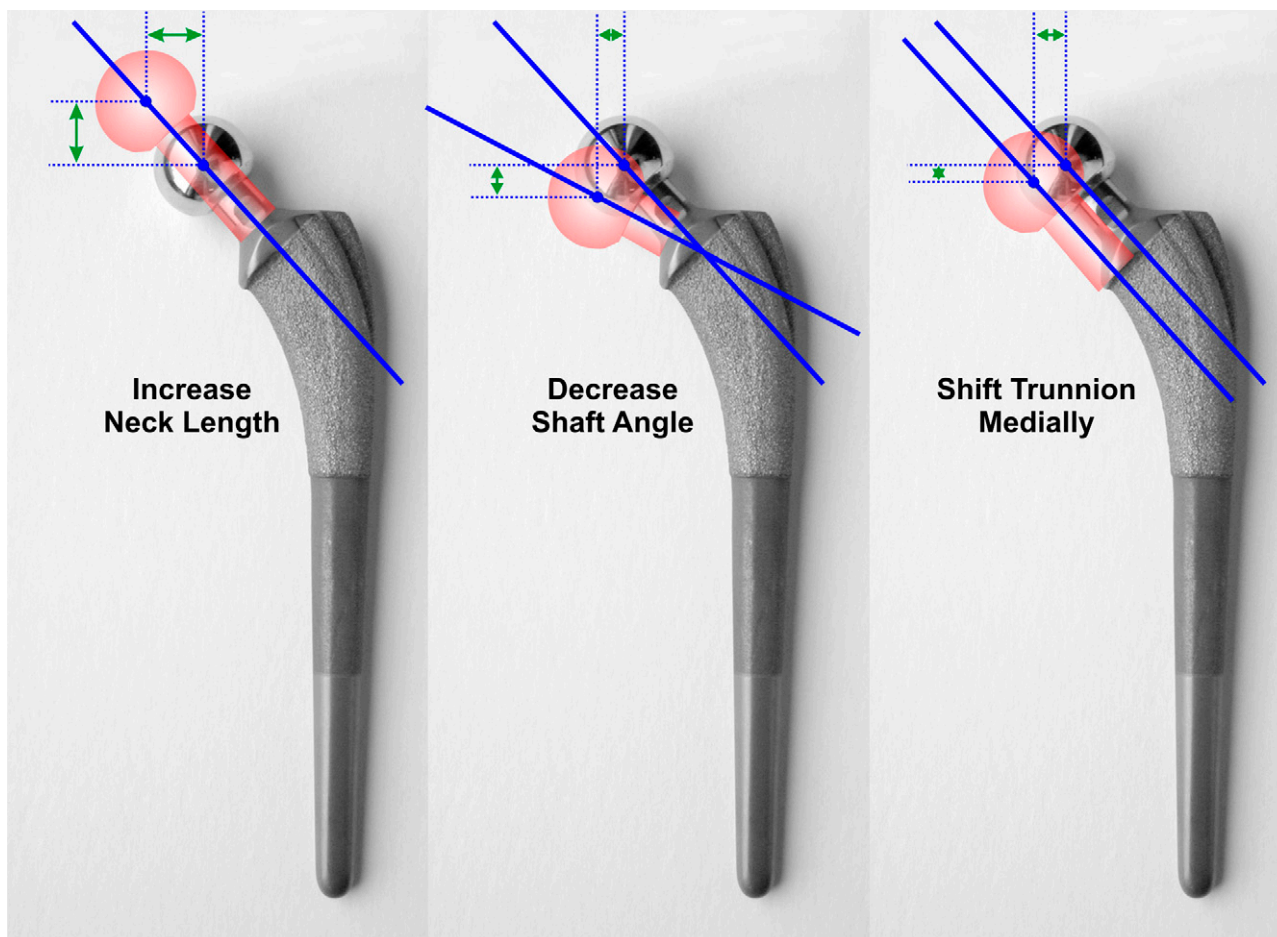


Fig. 8

Various methods of restoring offset with use of the femoral stem. (Printed with permission of Joint Implant Surgeons, Inc., New Albany, Ohio.)

can provide the surgeon with an assessment of the overall tightness of the reconstructed hip. The shuck test is performed by attempting to distract the total hip prosthesis in an inferior direction to assess the soft-tissue tension. The drop-kick test is performed by placing the hip in extension, flexing the knee to 90°, and releasing the lower limb to assess the amount of recoil as the knee springs back toward extension. In addition, intraoperative motion of the hip is important to evaluate for potential bone or prosthetic impingement and prosthetic stability. These intraoperative assessments coupled with proper preoperative templating should allow the surgeon to restore proper hip offset and limb length.

#### Measuring Limb Length

Substantial limb length discrepancy occurs after up to 3% of total hip

arthroplasties, but the clinical relevance is not known<sup>69</sup>. The definition of clinically relevant limb length discrepancy is not universally agreed on, with a range between 6 and 35 mm having been reported<sup>196-99</sup>. Most authors have agreed that discrepancies of <1 cm are well tolerated<sup>97</sup>. Edwards et al. reported average lengthening of 2.7 cm and 4.4 cm in twenty-three total hip arthroplasties complicated by peroneal and sciatic nerve palsy, respectively<sup>71</sup>. White and Dougall reported that lengthening of up to 35 mm does not affect clinical results<sup>99</sup>. Edeen et al. reported that 32% of patients who had a total hip arthroplasty were aware of a limb length inequality<sup>37</sup>. Relevant limb length discrepancy results in a limp, low-back pain, and functional impairment and is a major cause of litigation<sup>38,100</sup>. There are several methods for

intraoperative assessment of limb length, with varied degrees of accuracy, technical difficulty, and expense. Many of the methods involve an intraoperative measuring device, which may also enable measurement of offset<sup>41,63,101-103</sup>. These instruments measure from a fixed point on the pelvis to a fixed point on the femur and are used before femoral head dislocation and after total hip arthroplasty reconstruction. They are accurate if the position of the limb before the dislocation is correctly reproduced for the post-arthroplasty measurement<sup>104</sup>. There is a learning curve with these devices as well as the need for additional operative time and expense. An average limb lengthening of 3.4 mm was observed with the use of one specific device; limb lengthening of >12 mm was observed in 5% of cases, and 7% had symptomatic lengthening requiring a heel lift<sup>103</sup>.

Alternatively, preoperative templating and intraoperative “well-leg” referencing for limb length is as accurate as other methods, with few radiographic outliers<sup>56</sup>. Preoperative templating is performed. The center of the acetabulum on the normal, contralateral side is identified with acetabular templates (Fig. 6). The femoral component size and osteotomy level are determined, and the neck length is selected. The level of the femoral neck osteotomy is referenced intraoperatively with regard to the greater trochanter, the lesser trochanter, the piriformis fossa, or the distance from the center of the resected head. Direct

measurement of limb length with the patient supine is performed before positioning for the total hip arthroplasty and preparation of the extremity. This measurement is correlated with the preoperative templating. The patient is positioned in the lateral decubitus position and the uninvolved lower limb is used as a reference, with the relative difference felt at the patellar tendon (Fig. 9). The relative difference is reassessed after trial components have been placed. In one series of 410 patients treated with a primary total hip arthroplasty, an average lengthening of 3.9 mm was seen and only two patients perceived a limb length discrepancy<sup>56</sup>.

#### Implant-Related Factors

Femoral head size affects hip stability after a total hip arthroplasty<sup>13,105-107</sup>. Dislocation rates for all approaches decrease as femoral head size increases from 22 mm to 32 mm<sup>13</sup>. Smith et al. reported no dislocations when a 38-mm head had been used<sup>108</sup>. Cuckler et al. also reported no dislocations with use of 38-mm heads, but 2.5% of total hip prostheses with a 28-mm head dislocated<sup>109</sup>. Peters et al. found no dislocations with 38-mm heads, a 0.4% rate with 38 to 56-mm heads, and a 2.5% rate with 28-mm heads<sup>110</sup>. Smit studied anatomically sized femoral heads (femoral heads with a size that was 6 mm less

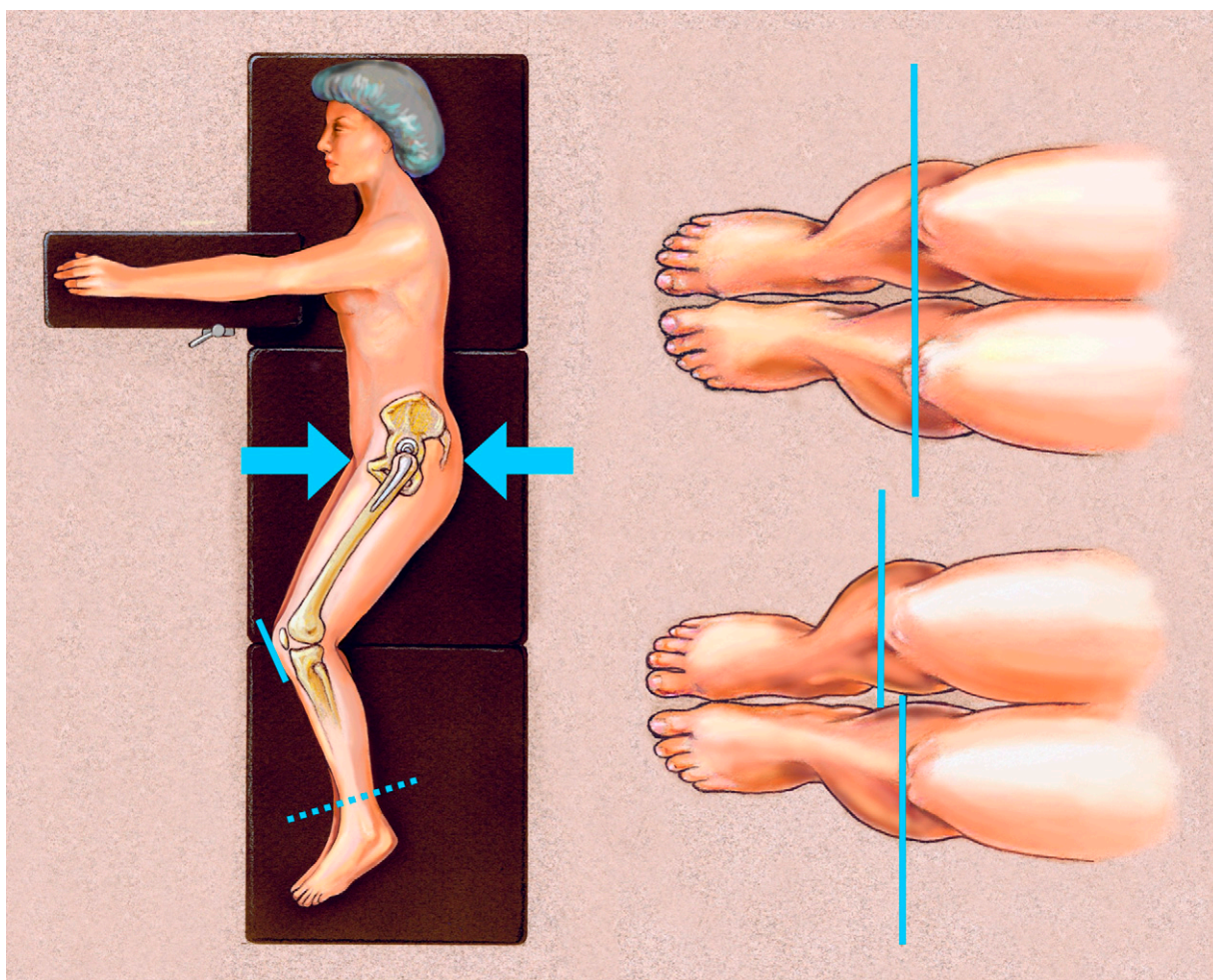


Fig. 9

With the patient in a lateral position, the uninvolved lower limb is used to reference limb lengths intraoperatively. The pelvis needs to be perpendicular to the floor. With the feet symmetrically positioned, the patellar tendons are palpated, and the limb length difference is assessed. The goal is to have symmetric positioning of the patellar tendons with the pelvis and feet. (Printed with permission of Joint Implant Surgeons, Inc., New Albany, Ohio.)



than the acetabular size) in primary total hip arthroplasties, and reported no dislocations at the time of a one-year follow-up<sup>111</sup>. Others believe that a good capsular repair as well as a larger femoral head protects against a dislocation. Lachiewicz and Soileau found that, when a formal posterior capsular repair had been employed, there was no change in the dislocation risk associated with 36 and 40-mm metal femoral heads compared with that for historical controls with standard-sized heads<sup>112</sup>. Despite the overall impressive reduction in the dislocation rate associated with large femoral heads in the above studies, Amstutz et al. reported a dislocation rate of 3.5% with use of large femoral heads in primary total hip arthroplasty<sup>113</sup>. However, Amstutz et al. demonstrated an advantage of using larger heads in revision total hip arthroplasties<sup>113</sup>. In addition, the use of large heads increases volumetric wear, and a thinner polyethylene acetabular liner is needed to accommodate the larger head. To avoid the adverse mechanical and fatigue properties associated with thin liners, implant companies commonly offer offset liners to increase polyethylene thickness<sup>114</sup>. Offset liners may increase femoral offset, and this affects the joint mechanics as previously discussed.

### Management of Instability

An accurate and complete patient history is critical for defining the cause of hip instability. Operative records are reviewed to determine the surgical approach, type of soft-tissue repair, and specific implant utilized, including the manufacturer's implant stickers if possible. The mechanism of the dislocation may be evaluated according to the direction of dislocation and the position of instability. Limb length, associated skeletal conditions such as scoliosis and contractures, neurological function of both the affected limb and the abductors, and the overall neurological function of the patient should be assessed. A thorough evaluation for infection is necessary<sup>115</sup>.

Radiographic studies are essential. Anteroposterior and true lateral views of the hip and an anteroposterior view

of the pelvis are the minimal imaging studies needed for these patients. Limb length differences, femoral offset, the status of the greater trochanter, and the component orientation are noted. A preoperative computed tomography scan to evaluate the position of the acetabular cup can provide important information regarding acetabular version<sup>116-119</sup>. Following evaluation and definition of the etiology of the dislocation, a treatment algorithm is established<sup>120,121</sup>.

The treatment options include closed reduction of the dislocated hip with or without bracing, total hip arthroplasty component revision, exchange of modular parts, cementing a liner into a well-fixed acetabular shell, bipolar or tripolar arthroplasty, utilization of a large femoral head, use of a constrained liner, advancement of the greater trochanter, and soft-tissue augmentation<sup>122-129</sup>. An understanding of the risk factors, causes of dislocation, and management options enables the surgeon to effectively minimize the incidence of dislocation after total hip arthroplasty as well as to establish a strategy for treating a patient with an unstable total hip prosthesis.

### Treatment Indications

Selection of the appropriate treatment option is guided by the cause and timing of the dislocation. Early dislocations occur within the first three to six months after the operation, and in the majority of patients a single episode of dislocation can be adequately treated with closed reduction<sup>130</sup>. The role of cast-bracing or casting is controversial, and there are data supporting and refuting the use of this treatment after reduction of the hip<sup>123,126,129</sup>. Late dislocations are those that occur five years or more after the index procedure. Patients with a first-time late dislocation are at high risk for recurrent instability<sup>131</sup>. Late dislocations have multiple possible causes, including polyethylene wear, trauma, decline in neurological function, increased soft-tissue laxity, or malposition of a total hip arthroplasty component<sup>132</sup>. Dislocations termed *intermediate* occur between six months

and five years after the total hip arthroplasty. Patients in whom this is the first dislocation can usually be managed with closed reduction. Surgical management should be considered for patients with recurrent instability following the initial closed reduction<sup>73,132</sup>. Successful operative management is critically dependent on accurate identification of the cause(s) of instability<sup>133</sup>.

### Techniques and Results of Revision Total Hip Arthroplasty for Instability

Component revision is indicated when implants are seen to be malpositioned on radiographs, computed tomography scans, or intraoperative evaluation<sup>118,119</sup>. Malpositioning of acetabular and femoral implants, limb length inequality, and improper femoral offset can be corrected and restored in a reasonably predictable fashion with component revision<sup>11,58,120,134</sup>. Perhaps the easiest and most attractive option for managing recurrent instability in the presence of implants that appear to be in an appropriate position and alignment is modular component exchange, or so-called dry revision<sup>135</sup>. This option is only indicated, however, if the components are reasonably well positioned<sup>136</sup>. Increasing the head size and/or neck length and changing the acetabular liner are among the simplest solutions. Varying degrees of success with this approach have been reported in multiple small series. Toomey et al. successfully prevented recurrent dislocation with modular component exchange in twelve of thirteen hips, although three hips dislocated once during the follow-up period<sup>136</sup>. Importantly, these modular revisions also included excision of soft tissue and bone causing impingement in ten hips<sup>136</sup>. Nine of the hips were converted to either a lipped-bearing implant or an implant with a higher degree of lipped bearing<sup>136</sup>. In another study, liner exchange was successful in 82% of cases of late instability associated with polyethylene wear<sup>137</sup>. In contrast, Barrack et al. reported multiple complications with modular component exchange, including liner disassociation and impingement, instability, and femoral head dislodgement from the stem trunnion<sup>88</sup>.

In cases of polyethylene-wear-related instability, cementing a new liner into a well-fixed shell may provide an alternative to complete revision if the components are oriented correctly<sup>138,139</sup>.

High-walled liners can be valuable for treating or preventing dislocation of well-positioned components, as reported by Cobb et al.<sup>140</sup>. Similarly, in revision total hip arthroplasty, an augmentation device can act as an elevated-rim liner. McConway et al. reported a 1.6% dislocation rate in 307 patients treated with revision total hip arthroplasty with a posterior lip-augmentation device<sup>141</sup>. Adding an augmentation device to the existing liner or socket has also been described and is effective in certain cases<sup>142-144</sup>. Currently, high-wall or lipped liners are used more sparingly because of concerns regarding impingement, wear, and limited hip motion.

Large femoral heads increase the head-neck ratio, thereby increasing the range of motion before impingement occurs, and increase the jump distance required for the head to dislocate<sup>107</sup>. In a series in which large femoral heads (36 mm and larger) were used, Beaulé et al. reported that >90% of the hips had no more instability after an average duration of follow-up of 6.5 years and only one had recurrent instability<sup>145</sup>. Amstutz et al. reported that the dislocation rate after revisions for recurrent instability was higher than that after revisions for other etiologies<sup>113</sup>. More troubling results were reported by Skeels et al., who observed a 17% rate of recurrent dislocation in patients who had undergone revision surgery with use of a femoral head that was 36 mm or larger<sup>146</sup>.

Another, less commonly utilized strategy to manage instability involves soft-tissue augmentation, or reinforcement of the hip abductor muscles and/or the posterior aspect of the hip capsule<sup>19</sup>. Reconstructions with an Achilles tendon allograft and a bone block, fascia lata, or a synthetic ligament have all been reported<sup>147-149</sup>. Indications for these procedures are unclear but may include deficiency of the hip abductor muscles or posterior aspect of the hip capsule in the setting of well-positioned, well-fixed total hip arthroplasty components.

Trochanteric advancement has been advocated for patients with well-positioned, well-fixed total hip arthroplasty implants<sup>124,150,151</sup>. Nonunion of the greater trochanter is a major concern and trochanter-related hip pain is common. Ekelund<sup>124</sup> and Kaplan et al.<sup>151</sup> independently reported 80% success rates with use of this approach in twenty-one patients each with recurrent dislocation and properly oriented components. Similarly, trochanteric osteotomy and advancement can be utilized for complex primary total hip arthroplasty to enhance stability<sup>152</sup>.

Bipolar arthroplasty is based on the principle of increasing the overall range of motion with articulation at two different bearing surfaces<sup>133,153,154</sup>. This provides a greater safe arc of motion before dislocation occurs and optimizes head-neck ratios while providing a larger jump distance. Parvizi and Morrey reported the elimination of recurrent dislocation in 81% of twenty-seven hips<sup>133</sup>. Attarian<sup>153</sup> and Ries and Wiedel<sup>154</sup> achieved 100% success using this technique. Medial and/or superior migration of the prosthesis, with resultant groin pain, is a concern if this technique is used.

Unconstrained tripolar hip arthroplasty utilizes a bipolar head to articulate with an acetabular shell and liner, and this combination increases the head-neck ratio and the jump distance<sup>155-157</sup>. Grigoris et al.<sup>156</sup> and Beaulé et al.<sup>155</sup> used an unconstrained tripolar implant to successfully treat instability without compromising acetabular fixation in 95% of their cases. Levine et al. reported a 93% success rate in a series of thirty-one patients in whom an unstable total hip prosthesis had been treated with an unconstrained tripolar construct<sup>157</sup>.

The final salvage option involves the use of a constrained acetabular liner<sup>19,158-170</sup>. Indications for this technique include hip abductor deficiency, neurological impairment, low-demand patients with well-fixed components, instability for which the cause cannot be determined, and persistent intraoperative instability<sup>19,122,127,158,167,168</sup>. Constrained acetabular liners reduce the hip motion prior to impingement and

therefore increase the risk of impingement and the acetabular shear stresses, which could lead to accelerated wear, loosening, or failure of fixation. These implants can be cemented into a well-fixed acetabular shell to reduce the morbidity of revision total hip arthroplasty<sup>138</sup>. Callaghan et al. reported no dislocations and two liner failures (a 94% success rate) with the use of this technique in patients with a well-fixed, well-positioned cementless acetabular shell<sup>163</sup>. This procedure is considered a low-morbidity treatment option in the setting of a well-fixed, properly oriented acetabular component, especially in older, low-demand patients<sup>163</sup>.

Favorable results with the use of constrained devices have been reported in several studies, but the use of these components should be considered only if no other treatment options are available<sup>171</sup>. At an average of 10.2 years after the use of fifty-six constrained tripolar devices, Goetz et al. reported a 7% failure rate secondary to recurrent dislocation, osteolysis, or aseptic loosening<sup>164,165</sup>. Bremner et al. reported similar results, with a 6% failure rate secondary to recurrent dislocation or liner failure at 10.2 years<sup>161</sup>. There is concern about the stability of fixation of constrained devices. Shrader et al. noted that, while no dislocations were seen, there were acetabular cup radiolucencies in 14% of their cases<sup>169</sup>. Su and Pellicci reported a 98% rate of success in terms of preventing instability in eighty-five hips with a constrained tripolar implant<sup>170</sup>. There are modes of failure specific to tripolar constrained devices<sup>172-174</sup>. Guyen et al. reported forty-three failures of tripolar constrained devices, with four types of failure, including the bone-implant interface, the mechanism holding the constrained acetabular liner to the metal shell, the locking mechanism of the bipolar component, and dislocation of the head at the inner bearing<sup>173</sup>. Methods for closed reduction of a constrained component have been described, but long-term outcomes have not yet been reported<sup>175</sup>.

One of us (K.R.B.) and colleagues reported on 755 alternatively designed

constrained total hip arthroplasty components with a capture mechanism and locking ring design<sup>159</sup>. The dislocation rate for the 667 hips followed for ten years was 17.5%, and aseptic loosening of the cup and stem were also major long-term causes of failure that required a reoperation<sup>159</sup>. Newer designs allowing greater hip motion prior to impingement have been introduced. One of us (K.R.B.) and colleagues reported a 99% rate of success in terms of preventing recurrent dislocation in a group of eighty-one total hip arthroplasty revisions done with a novel constrained device<sup>160</sup>.

### Overview

In conclusion, the intraoperative challenge of achieving stability and limb length equality after total hip arthroplasty starts with preoperative planning, including physical examination, radiographic evaluation, templating, and aligning patient and surgeon expectations. Each surgical approach has advantages and disadvantages in terms of stability and limb length. It is the responsibility of the surgeon to be familiar with the drawbacks and bene-

fits of each approach and to utilize a method that most easily accomplishes the goals of a stable prosthetic construct, hip stability, and restoration of limb length equality. Familiarity and experience with a total hip arthroplasty technique reduce the risk of dislocation and limb length inequality. Intraoperatively, the prosthetic design including the femoral head size and femoral offset, component orientation, and reconstruction of the hip soft tissues are the critical variables for achieving success. Preoperative radiographic templating is paramount, and intraoperative maneuvers to determine limb length are important for obtaining the best result. Dislocation continues to be a major mode of failure of total hip arthroplasty. Obtaining a stable hip at the time of the initial total hip arthroplasty reduces the risk of this complication.

Keith R. Berend, MD  
Michael J. Morris, MD  
Joint Implant Surgeons, Inc.,  
7277 Smith's Mill Road, Suite 200,

New Albany, OH 43054.  
E-mail address for K.R. Berend:  
berendkr@joint-surgeons.com

Scott M. Sporer, MD  
Department of Orthopedics,  
Rush University Medical Center,  
1725 West Harrison Street,  
Suite 1063,  
Chicago, IL 60612

Rafael J. Sierra, MD  
Department of Orthopedic Surgery,  
Mayo Clinic College of Medicine,  
200 First Street S.W., Rochester,  
MN 55905

Andrew H. Glassman, MD, MS  
Department of Orthopedics,  
Ohio State University,  
1491 East Broad Street, Columbus,  
OH 43205

Printed with permission of the American Academy of Orthopaedic Surgeons. This article, as well as other lectures presented at the Academy's Annual Meeting, will be available in February 2011 in *Instructional Course Lectures*, Volume 60. The complete volume can be ordered online at [www.aaos.org](http://www.aaos.org), or by calling 800-626-6726 (8 A.M.-5 P.M., Central time).

### References

- Bourne RB, Maloney WJ, Wright JG. An AOA critical issue. The outcome of the outcomes movement. *J Bone Joint Surg Am.* 2004;86:633-40.
- Chang RW, Pellisier JM, Hazen GB. A cost-effectiveness analysis of total hip arthroplasty for osteoarthritis of the hip. *JAMA.* 1996;275:858-65.
- Bozic KJ, Kurtz SM, Lau E, Ong K, Vail TP, Berry DJ. The epidemiology of revision total hip arthroplasty in the United States. *J Bone Joint Surg Am.* 2009;91:128-33.
- Goldstein WM, Gordon A, Branson JJ. Leg length inequality in total hip arthroplasty. *Orthopedics.* 2005;28(9 Suppl):s1037-40.
- Khatod M, Barber T, Paxton E, Namba R, Fithian D. An analysis of the risk of hip dislocation with a contemporary total joint registry. *Clin Orthop Relat Res.* 2006;447:19-23.
- Kurtz S, Ong K, Lau E, Mowat F, Halpern M. Projections of primary and revision hip and knee arthroplasty in the United States from 2005 to 2030. *J Bone Joint Surg Am.* 2007;89:780-5.
- Levy RN, Levy CM, Snyder J, Digiovanni J. Outcome and long-term results following total hip replacement in elderly patients. *Clin Orthop Relat Res.* 1995;316:25-30.
- Phillips CB, Barrett JA, Losina E, Mahomed NN, Lingard EA, Guadagnoli E, Baron JA, Harris WH, Poss R, Katz JN. Incidence rates of dislocation, pulmonary embolism, and deep infection during the first six months after elective total hip replacement. *J Bone Joint Surg Am.* 2003;85:20-6.
- Sanchez-Sotelo J, Haidukewych GJ, Boberg CJ. Hospital cost of dislocation after primary total hip arthroplasty. *J Bone Joint Surg Am.* 2006;88:290-4.
- Abraham WD, Dimon JH 3rd. Leg length discrepancy in total hip arthroplasty. *Orthop Clin North Am.* 1992;23:201-9.
- Alberton GM, High WA, Morrey BF. Dislocation after revision total hip arthroplasty: an analysis of risk factors and treatment options. *J Bone Joint Surg Am.* 2002;84:1788-92.
- Berry DJ, von Knoch M, Schleck CD, Harmsen WS. The cumulative long-term risk of dislocation after primary Charnley total hip arthroplasty. *J Bone Joint Surg Am.* 2004;86:9-14.
- Berry DJ, von Knoch M, Schleck CD, Harmsen WS. Effect of femoral head diameter and operative approach on risk of dislocation after primary total hip arthroplasty. *J Bone Joint Surg Am.* 2005;87:2456-63.
- Callaghan JJ, Templeton JE, Liu SS, Pedersen DR, Goetz DD, Sullivan PM, Johnston RC. Results of Charnley total hip arthroplasty at a minimum of thirty years. A concise follow-up of a previous report. *J Bone Joint Surg Am.* 2004;86:690-5.
- Conroy JL, Whitehouse SL, Graves SE, Pratt NL, Ryan P, Crawford RW. Risk factors for revision for early dislocation in total hip arthroplasty. *J Arthroplasty.* 2008;23:867-72.
- Eftekhari NS. Dislocation and instability complicating low friction arthroplasty of the hip joint. *Clin Orthop Relat Res.* 1976;121:120-5.
- Heithoff BE, Callaghan JJ, Goetz DD, Sullivan PM, Pedersen DR, Johnston RC. Dislocation after total hip arthroplasty: a single surgeon's experience. *Orthop Clin North Am.* 2001;32:587-91, viii.
- Lewinnek GE, Lewis JL, Tarr R, Compere CL, Zimmerman JR. Dislocations after total hip-replacement arthroplasties. *J Bone Joint Surg Am.* 1978;60:217-20.
- Parvizi J, Picinic E, Sharkey PF. Revision total hip arthroplasty for instability: surgical techniques and principles. *J Bone Joint Surg Am.* 2008;90:1134-42.
- Ritter MA. Dislocation and subluxation of the total hip replacement. *Clin Orthop Relat Res.* 1976;121:92-4.
- Woo RY, Morrey BF. Dislocations after total hip arthroplasty. *J Bone Joint Surg Am.* 1982;64:1295-306.
- Sadr Azodi O, Adami J, Lindström D, Eriksson KO, Wladis A, Bellocco R. High body mass index is associated with increased risk of implant dislocation following primary total hip replacement: 2,106 patients followed for up to 8 years. *Acta Orthop.* 2008;79:141-7.

- 23.** Ekelund A, Rydell N, Nilsson OS. Total hip arthroplasty in patients 80 years of age and older. *Clin Orthop Relat Res.* 1992;281:101-6.
- 24.** Jibodh SR, Gurkan I, Wenz JF. In-hospital outcome and resource use in hip arthroplasty: influence of body mass. *Orthopedics.* 2004;27:594-601.
- 25.** Jolles BM, Zangger P, Leyvraz PF. Factors predisposing to dislocation after primary total hip arthroplasty: a multivariate analysis. *J Arthroplasty.* 2002;17:282-8.
- 26.** Kim Y, Morshed S, Joseph T, Bozic K, Ries MD. Clinical impact of obesity on stability following revision total hip arthroplasty. *Clin Orthop Relat Res.* 2006;453:142-6.
- 27.** Krenzel BA, Berend ME, Malinzak RA, Faris PM, Keating EM, Meding JB, Ritter MA. High preoperative range of motion is a significant risk factor for dislocation in primary total hip arthroplasty. *J Arthroplasty.* 2010 Jun 10 [Epub ahead of print].
- 28.** Lachiewicz PF, Soileau ES. Stability of total hip arthroplasty in patients 75 years or older. *Clin Orthop Relat Res.* 2002;405:65-9.
- 29.** Lee BP, Berry DJ, Harmsen WS, Sim FH. Total hip arthroplasty for the treatment of an acute fracture of the femoral neck: long-term results. *J Bone Joint Surg Am.* 1998;80:70-5.
- 30.** Meek RM, Allan DB, McPhillips G, Kerr L, Howie CR. Epidemiology of dislocation after total hip arthroplasty. *Clin Orthop Relat Res.* 2006;447:9-18.
- 31.** Morrey BF. Instability after total hip arthroplasty. *Orthop Clin North Am.* 1992;23:237-48.
- 32.** Morrey BF. Difficult complications after hip joint replacement. Dislocation. *Clin Orthop Relat Res.* 1997;344:179-87.
- 33.** Zwartelé RE, Brand R, Doets HC. Increased risk of dislocation after primary total hip arthroplasty in inflammatory arthritis: a prospective observational study of 410 hips. *Acta Orthop Scand.* 2004;75:684-90.
- 34.** Battaglia TC, Mulhall KJ, Brown TE, Saleh KJ. Increased surgical volume is associated with lower THA dislocation rates. *Clin Orthop Relat Res.* 2006;447:28-33.
- 35.** Katz JN, Losina E, Barrett J, Phillips CB, Mahomed NN, Lew RA, Guadagnoli E, Harris WH, Poss R, Baron JA. Association between hospital and surgeon procedure volume and outcomes of total hip replacement in the United States Medicare population. *J Bone Joint Surg Am.* 2001;83:1622-9.
- 36.** Austin MS, Hozack WJ, Sharkey PF, Rothman RH. Stability and leg length equality in total hip arthroplasty. *J Arthroplasty.* 2003;18(3 Suppl 1):88-90.
- 37.** Edeen J, Sharkey PF, Alexander AH. Clinical significance of leg-length inequality after total hip arthroplasty. *Am J Orthop (Belle Mead NJ).* 1995;24:347-51.
- 38.** Parvizi J, Sharkey PF, Bissett GA, Rothman RH, Hozack WJ. Surgical treatment of limb-length discrepancy following total hip arthroplasty. *J Bone Joint Surg Am.* 2003;85:2310-7.
- 39.** Ranawat CS, Rodriguez JA. Functional leg-length inequality following total hip arthroplasty. *J Arthroplasty.* 1997;12:359-64.
- 40.** Charles MN, Bourne RB, Davey JR, Greenwald AS, Morrey BF, Rorabeck CH. Soft-tissue balancing of the hip: the role of femoral offset restoration. *Instr Course Lect.* 2005;54:131-41.
- 41.** Itokazu M, Masuda K, Ohno T, Itoh Y, Takatsu T, Wenyi Y. A simple method of intraoperative limb length measurement in total hip arthroplasty. *Bull Hosp Joint Dis.* 1997;56:204-5.
- 42.** Berend KR, Lombardi AV Jr, Seng BE, Adams JB. Enhanced early outcomes with the anterior supine intermuscular approach in primary total hip arthroplasty. *J Bone Joint Surg Am* 2009;91 Suppl 6:107-20.
- 43.** Kennon RE, Keggi JM, Wetmore RS, Zatorski LE, Huo MH, Keggi KJ. Total hip arthroplasty through a minimally invasive anterior surgical approach. *J Bone Joint Surg Am.* 2003;85 Suppl 4:39-48.
- 44.** Matta JM, Shahrdrar C, Ferguson T. Single-incision anterior approach for total hip arthroplasty on an orthopaedic table. *Clin Orthop Relat Res.* 2005;441:115-24.
- 45.** Seng BE, Berend KR, Ajluni AF, Lombardi AV Jr. Anterior-supine minimally invasive total hip arthroplasty: defining the learning curve. *Orthop Clin North Am.* 2009;40:343-50.
- 46.** Light TR, Keggi KJ. Anterior approach to hip arthroplasty. *Clin Orthop Relat Res.* 1980;152:255-60.
- 47.** Berger RA. Total hip arthroplasty using the minimally invasive two-incision approach. *Clin Orthop Relat Res.* 2003;417:232-41.
- 48.** Berger RA. Mini-incision total hip replacement using an anterolateral approach: technique and results. *Orthop Clin North Am.* 2004;35:143-51.
- 49.** Archibeck MJ, White RE Jr. Learning curve for the two-incision total hip replacement. *Clin Orthop Relat Res.* 2004;429:232-8.
- 50.** Berry DJ, Berger RA, Callaghan JJ, Dorr LD, Duwelius PJ, Hartzband MA, Lieberman JR, Mears DC. Minimally invasive total hip arthroplasty. Development, early results, and a critical analysis. Presented at the Annual Meeting of the American Orthopaedic Association, Charleston, South Carolina. *J Bone Joint Surg Am.* 2003;85:2235-46.
- 51.** Bal BS, Haltom D, Aleto T, Barrett M. Early complications of primary total hip replacement performed with a two-incision minimally invasive technique. *J Bone Joint Surg Am.* 2005;87:2432-8.
- 52.** Mardones R, Pagnano MW, Nemanich JP, Trousdale RT. The Frank Stinchfield Award: muscle damage after total hip arthroplasty done with the two-incision and mini-posterior techniques. *Clin Orthop Relat Res.* 2005;441:63-7.
- 53.** Pagnano MW, Leone J, Lewallen DG, Hanssen AD. Two-incision THA had modest outcomes and some substantial complications. *Clin Orthop Relat Res.* 2005;441:86-90.
- 54.** Hardinge K. The direct lateral approach to the hip. *J Bone Joint Surg Br.* 1982;64:17-9.
- 55.** Mallory TH, Lombardi AV Jr, Fada RA, Herrington SM, Eberell RW. Dislocation after total hip arthroplasty using the anterolateral abductor split approach. *Clin Orthop Relat Res.* 1999;358:166-72.
- 56.** Iagulli ND, Mallory TH, Berend KR, Lombardi AV Jr, Russell JH, Adams JB, Groseth KL. A simple and accurate method for determining leg length in primary total hip arthroplasty. *Am J Orthop (Belle Mead NJ).* 2006;35:455-7.
- 57.** Demos HA, Rorabeck CH, Bourne RB, MacDonald SJ, McCalden RW. Instability in primary total hip arthroplasty with the direct lateral approach. *Clin Orthop Relat Res.* 2001;393:168-80.
- 58.** Ritter MA, Harty LD, Keating ME, Faris PM, Meding JB. A clinical comparison of the anterolateral and posterolateral approaches to the hip. *Clin Orthop Relat Res.* 2001;385:95-9.
- 59.** Kenny P, O'Brien CP, Synnott K, Walsh MG. Damage to the superior gluteal nerve after two different approaches to the hip. *J Bone Joint Surg Br.* 1999;81:979-81.
- 60.** Goldstein WM, Gleason TF, Kopplin M, Branson JJ. Prevalence of dislocation after total hip arthroplasty through a posterolateral approach with partial capsulotomy and capsulorrhaphy. *J Bone Joint Surg Am.* 2001;83 Suppl 2(Pt 1):2-7.
- 61.** Woolson ST, Mow CS, Syquia JF, Lannin JV, Schurman DJ. Comparison of primary total hip replacements performed with a standard incision or a mini-incision. *J Bone Joint Surg Am.* 2004;86:1353-8.
- 62.** Ogonda L, Wilson R, Archbold P, Lawlor M, Humphreys P, O'Brien S, Beverland D. A minimal-incision technique in total hip arthroplasty does not improve early postoperative outcomes. A prospective, randomized, controlled trial. *J Bone Joint Surg Am.* 2005;87:701-10.
- 63.** Huddleston HD. An accurate method for measuring leg length and hip offset in hip arthroplasty. *Orthopedics.* 1997;20:331-2.
- 64.** Masonis JL, Bourne RB. Surgical approach, abductor function, and total hip arthroplasty dislocation. *Clin Orthop Relat Res.* 2002;405:46-53.
- 65.** Chiu FY, Chen CM, Chung TY, Lo WH, Chen TH. The effect of posterior capsulorrhaphy in primary total hip arthroplasty: a prospective randomized study. *J Arthroplasty.* 2000;15:194-9.
- 66.** Pellicci PM, Bostrom M, Poss R. Posterior approach to total hip replacement using enhanced posterior soft tissue repair. *Clin Orthop Relat Res.* 1998;355:224-8.
- 67.** Sierra RJ, Raposo JM, Trousdale RT, Cabanela ME. Dislocation of primary THA done through a posterolateral approach in the elderly. *Clin Orthop Relat Res.* 2005;441:262-7.
- 68.** Suh KT, Park BG, Choi YJ. A posterior approach to primary total hip arthroplasty with soft tissue repair. *Clin Orthop Relat Res.* 2004;418:162-7.
- 69.** Weeden SH, Paprosky WG, Bowling JW. The early dislocation rate in primary total hip arthroplasty following the posterior approach with posterior soft-tissue repair. *J Arthroplasty.* 2003;18:709-13.
- 70.** Kim YS, Kwon SY, Sun DH, Han SK, Maloney WJ. Modified posterior approach to total hip arthroplasty to enhance joint stability. *Clin Orthop Relat Res.* 2008;466:294-9.
- 71.** Edwards BN, Tulles HS, Noble PC. Contributory factors and etiology of sciatic nerve palsy in total hip arthroplasty. *Clin Orthop Relat Res.* 1987;218:136-41.
- 72.** Navarro RA, Schmalzried TP, Amstutz HC, Dorey FJ. Surgical approach and nerve palsy in total hip arthroplasty. *J Arthroplasty.* 1995;10:1-5.
- 73.** Lachiewicz PF. Dislocation. In: Hozack WJ, Parvizi J, Bender B, editors. *Surgical treatment of hip arthritis: reconstruction, replacement, and revision.* Philadelphia: Saunders Elsevier; 2010. p 429-36.
- 74.** Kadakia NR, Noble PC, Sugano N, Paravic V. Posterior dislocation of the artificial hip joint: effect of cup anteversion. *Orthop Trans.* 1998-1999;22:905-6.
- 75.** Paterno SA, Lachiewicz PF, Kelley SS. The influence of patient-related factors and the position of the acetabular component on the rate of dislocation after total hip replacement. *J Bone Joint Surg Am.* 1997;79:1202-10.
- 76.** Biedermann R, Tonin A, Krismer M, Rachbauer F, Eibl G, Stöckl B. Reducing the risk of dislocation after total hip arthroplasty: the effect of orientation of the acetabular component. *J Bone Joint Surg Br.* 2005;87:762-9.



- 77.** Hassan DM, Johnston GH, Dust WN, Watson G, Dolovich AT. Accuracy of intraoperative assessment of acetabular prosthesis placement. *J Arthroplasty*. 1998;13:80-4.
- 78.** Rittmeister M, Callitsis C. Factors influencing cup orientation in 500 consecutive total hip replacements. *Clin Orthop Relat Res*. 2006;445:192-6.
- 79.** McCollum DE, Gray WJ. Dislocation after total hip arthroplasty. Causes and prevention. *Clin Orthop Relat Res*. 1990;261:159-70.
- 80.** Archbold HA, Mockford B, Molloy D, McConway J, Ogonda L, Beverland D. The transverse acetabular ligament: an aid to orientation of the acetabular component during primary total hip replacement: a preliminary study of 1000 cases investigating postoperative stability. *J Bone Joint Surg Br*. 2006;88:883-6.
- 81.** Sotereanos NG, Miller MC, Smith B, Hube R, Sewecke JJ, Wohlrab D. Using intraoperative pelvic landmarks for acetabular component placement in total hip arthroplasty. *J Arthroplasty*. 2006;21:832-40.
- 82.** Honl M, Schwieger K, Salineros M, Jacobs J, Morlock M, Wimmer M. Orientation of the acetabular component. A comparison of five navigation systems with conventional surgical technique. *J Bone Joint Surg Br*. 2006;88:1401-5.
- 83.** Jaramaz B, DiGioia AM 3rd, Blackwell M, Nikou C. Computer assisted measurement of cup placement in total hip replacement. *Clin Orthop Relat Res*. 1998;354:70-81.
- 84.** Spencer JM, Day RE, Sloan KE, Beaver RJ. Computer navigation of the acetabular component: a cadaver reliability study. *J Bone Joint Surg Br*. 2006;88:972-5.
- 85.** McGrory BJ, Morrey BF, Calahan TD, An KN, Cabanela ME. Effect of femoral offset on range of motion and abductor muscle strength after total hip arthroplasty. *J Bone Joint Surg Br*. 1995;77:865-9.
- 86.** Herrlin K, Selvik G, Pettersson H, Kesek P, Onnerfält R, Ohlin A. Position, orientation and component interaction in dislocation of the total hip prosthesis. *Acta Radiol*. 1988;29:441-4.
- 87.** Widmer KH, Zurfluh B. Compliant positioning of total hip components for optimal range of motion. *J Orthop Res*. 2004;22:815-21.
- 88.** Barrack RL, Burke DW, Cook SD, Skinner HB, Harris WH. Complications related to modularity of total hip components. *J Bone Joint Surg Br*. 1993;75:688-92.
- 89.** Woolson ST, Hartford JM, Sawyer A. Results of a method of leg-length equalization for patients undergoing primary total hip replacement. *J Arthroplasty*. 1999;14:159-64.
- 90.** Bourne RB, Rorabeck CH. Soft tissue balancing: the hip. *J Arthroplasty*. 2002;17(4 Suppl 1):17-22.
- 91.** Longjohn D, Dorr LD. Soft tissue balance of the hip. *J Arthroplasty*. 1998;13:97-100.
- 92.** Asayama I, Naito M, Fujisawa M, Kambe T. Relationship between radiographic measurements of the reconstructed hip joint position and the Trendelenburg sign. *J Arthroplasty*. 2002;17:747-51.
- 93.** Sakalkale DP, Sharkey PF, Eng K, Hozack WJ, Rothman RH. Effect of femoral component offset on polyethylene wear in total hip arthroplasty. *Clin Orthop Relat Res*. 2001;388:125-34.
- 94.** Mineo R, Berend KR, Mallory TH, Lombardi AV Jr. A lateralized tapered titanium cementless femoral component does not increase thigh or trochanteric pain. *Surg Technol Int*. 2007;16:210-4.
- 95.** Incavo SJ, Havener T, Benson E, McGrory BJ, Coughlin KM, Beynon BD. Efforts to improve cementless femoral stems in THR: 2- to 5-year follow-up of a high-offset femoral stem with distal stem modification (Secur-Fit Plus). *J Arthroplasty*. 2004;19:61-7.
- 96.** Bhava A, Paley D, Herzenberg JE. Improvement in gait parameters after lengthening for the treatment of limb-length discrepancy. *J Bone Joint Surg Am*. 1999;81:529-34.
- 97.** Gurney B, Mermier C, Robergs R, Gibson A, Rivero D. Effects of limb-length discrepancy on gait economy and lower-extremity muscle activity in older adults. *J Bone Joint Surg Am*. 2001;83:907-15.
- 98.** Maloney WJ, Keeney JA. Leg length discrepancy after total hip arthroplasty. *J Arthroplasty*. 2004;19(4 Suppl 1):108-10.
- 99.** White TO, Dougall TW. Arthroplasty of the hip. Leg length is not important. *J Bone Joint Surg Br*. 2002;84:335-8.
- 100.** Ranawat CS, Rao RR, Rodriguez JA, Bhende HS. Correction of limb-length inequality during total hip arthroplasty. *J Arthroplasty*. 2001;16:715-20.
- 101.** Jasty M, Webster W, Harris W. Management of limb length inequality during total hip replacement. *Clin Orthop Relat Res*. 1996;333:165-71.
- 102.** Matsuda K, Nakamura S, Matsushita T. A simple method to minimize limb-length discrepancy after hip arthroplasty. *Acta Orthop*. 2006;77:375-9.
- 103.** Shiramizu K, Naito M, Shitama T, Nakamura Y, Shitama H. L-shaped caliper for limb length measurement during total hip arthroplasty. *J Bone Joint Surg Br*. 2004;86:966-9.
- 104.** Sarin VK, Pratt WR, Bradley GW. Accurate femur repositioning is critical during intraoperative total hip arthroplasty length and offset assessment. *J Arthroplasty*. 2005;20:887-91.
- 105.** Bartz RL, Noble PC, Kadakia NR, Tullos HS. The effect of femoral component head size on posterior dislocation of the artificial hip joint. *J Bone Joint Surg Am*. 2000;82:1300-7.
- 106.** Kung PL, Ries MD. Effect of femoral head size and abductors on dislocation after revision THA. *Clin Orthop Relat Res*. 2007;465:170-4.
- 107.** Sariali E, Lazennec JY, Khiami F, Catonné Y. Mathematical evaluation of jumping distance in total hip arthroplasty: influence of abduction angle, femoral head offset, and head diameter. *Acta Orthop*. 2009;80:277-82.
- 108.** Smith TM, Berend KR, Lombardi AV Jr, Emerson RH Jr, Mallory TH. Metal-on-metal total hip arthroplasty with large heads may prevent early dislocation. *Clin Orthop Relat Res*. 2005;441:137-42.
- 109.** Cuckler JM, Moore KD, Lombardi AV Jr, McPherson E, Emerson R. Large versus small femoral heads in metal-on-metal total hip arthroplasty. *J Arthroplasty*. 2004;19(8 Suppl 3):41-4.
- 110.** Peters CL, McPherson E, Jackson JD, Erickson JA. Reduction in early dislocation rate with large-diameter femoral heads in primary total hip arthroplasty. *J Arthroplasty*. 2007;22(6 Suppl 2):140-4.
- 111.** Smit MJ. Hip stability in primary total hip arthroplasty using an anatomically sized femoral head. *Orthopedics*. 2009;32:489.
- 112.** Lachiewicz PF, Soileau ES. Dislocation of primary total hip arthroplasty with 36 and 40-mm femoral heads. *Clin Orthop Relat Res*. 2006;453:153-5.
- 113.** Amstutz HC, Le Duff MJ, Beaulé PE. Prevention and treatment of dislocation after total hip replacement using large diameter balls. *Clin Orthop Relat Res*. 2004;429:108-16.
- 114.** Halley D, Glassman A, Crowninshield RD. Recurrent dislocation after revision total hip replacement with a large prosthetic femoral head. A case report. *J Bone Joint Surg Am*. 2004;86:827-30.
- 115.** Spangehl MJ, Masri BA, O'Connell JX, Duncan CP. Prospective analysis of preoperative and intraoperative investigations for the diagnosis of infection at the sites of two hundred and two revision total hip arthroplasties. *J Bone Joint Surg Am*. 1999;81:672-83.
- 116.** Barneir E, Dubowitz B, Roffman M. Computed tomography in the assessment and planning of complicated total hip replacement. *Acta Orthop Scand*. 1982;53:597-604.
- 117.** Lasda NA, Levinsohn EM, Yuan HA, Bunnell WP. Computerized tomography in disorders of the hip. *J Bone Joint Surg Am*. 1978;60:1099-102.
- 118.** Mian SW, Truchly G, Pflum FA. Computed tomography measurement of acetabular cup anteversion and retroversion in total hip arthroplasty. *Clin Orthop Relat Res*. 1992;276:206-9.
- 119.** Pierchon F, Pasquier G, Cotten A, Fontaine C, Clarisse J, Duquennoy A. Causes of dislocation of total hip arthroplasty. CT study of component alignment. *J Bone Joint Surg Br*. 1994;76:45-8.
- 120.** Dorr LD, Wan Z. Causes of and treatment protocol for instability of total hip replacement. *Clin Orthop Relat Res*. 1998;355:144-51.
- 121.** Ritter MA. A treatment plan for the dislocated total hip arthroplasty. *Clin Orthop Relat Res*. 1980;153:153-5.
- 122.** Cameron HU. Use of a constrained acetabular component in revision hip surgery. *Contemp Orthop*. 1991;23:481-4.
- 123.** Clayton ML, Thirupathi RG. Dislocation following total hip arthroplasty. Management by special brace in selected patients. *Clin Orthop Relat Res*. 1983;177:154-9.
- 124.** Ekelund A. Trochanteric osteotomy for recurrent dislocation of total hip arthroplasty. *J Arthroplasty*. 1993;8:629-32.
- 125.** LaPorte DM, Mont MA, Pierre-Jacques H, Peyton RS, Hungerford DS. Technique for acetabular liner revision in a non-modular metal-backed component. *J Arthroplasty*. 1998;13:348-50.
- 126.** Mallory TH, Vaughn BK, Lombardi AV Jr, Kraus TJ. Prophylactic use of a hip cast-brace following primary and revision total hip arthroplasty. *Orthop Rev*. 1988;17:178-83.
- 127.** Russin LA, Sonni A. Indications for the use of a constrained THR prosthesis. *Orthop Rev*. 1981;10:81-4.
- 128.** Sioen W, Simon JP, Labey L, Van Audekercke R. Posterior transosseous capsulotendinous repair in total hip arthroplasty: a cadaver study. *J Bone Joint Surg Am*. 2002;84:1793-8.
- 129.** Williams JF, Gottesman MJ, Mallory TH. Dislocation after total hip arthroplasty. Treatment with an above-knee hip spica cast. *Clin Orthop Relat Res*. 1982;171:53-8.
- 130.** Woolson ST, Rahimtoola ZO. Risk factors for dislocation during the first 3 months after primary total hip replacement. *J Arthroplasty*. 1999;14:662-8.
- 131.** von Knoch M, Berry DJ, Hamsen WS, Morrey BF. Late dislocation after total hip arthroplasty. *J Bone Joint Surg Am*. 2002;84:1949-53.

- 132.** Joshi A, Lee CM, Markovic L, Vlatits G, Murphy JC. Prognosis of dislocation after total hip arthroplasty. *J Arthroplasty*. 1998;13:17-21.
- 133.** Parvizi J, Morrey BF. Bipolar hip arthroplasty as a salvage treatment for instability of the hip. *J Bone Joint Surg Am*. 2000;82:1132-9.
- 134.** Olerud S, Karström G. Recurrent dislocation after total hip replacement. Treatment by fixing an additional sector to the acetabular component. *J Bone Joint Surg Br*. 1985;67:402-5.
- 135.** Hopper RH, McAuley JP, Engh CA. Modular component revision of recurrent dislocation of a total hip replacement in selected patients. *J Bone Joint Surg Am*. 2001;83:1529-33.
- 136.** Toomey SD, Hopper RH Jr, McAuley JP, Engh CA. Modular component exchange for treatment of recurrent dislocation of a total hip replacement in selected patients. *J Bone Joint Surg Am*. 2001;83:1529-33.
- 137.** Parvizi J, Wade FA, Rapuri V, Springer BD, Berry DJ, Hozack WJ. Revision hip arthroplasty for late instability secondary to polyethylene wear. *Clin Orthop Relat Res*. 2006;447:66-9.
- 138.** Beaulé PE, Ebramzadeh E, LeDuff M, Prasad R, Amstutz HC. Cementing a liner into a stable cementless acetabular shell: the double-socket technique. *J Bone Joint Surg Am*. 2004;86:929-34.
- 139.** Heck DA, Murray DG. In vivo construction of a metal-backed, high-molecular-weight polyethylene cup during McKee-Farrar revision total joint arthroplasty. A case report. *J Arthroplasty*. 1986;1:203-6.
- 140.** Cobb TK, Morrey BF, Ilstrup DM. The elevated-rim acetabular liner in total hip arthroplasty: relationship to postoperative dislocation. *J Bone Joint Surg Am*. 1996;78:80-6.
- 141.** McConway J, O'Brien S, Doran E, Archbold P, Beverland D. The use of a posterior lip augmentation device for a revision of recurrent dislocation after primary cemented Chamley/Chamley Elite total hip replacement: results at a mean follow-up of six years and nine months. *J Bone Joint Surg Br*. 2007;89:1581-5.
- 142.** Mogensen B, Arnason H, Jónsson GT. Socket wall addition for dislocating total hip. Report of two cases. *Acta Orthop Scand*. 1986;57:373-4.
- 143.** Rogers M, Blom AW, Barnett A, Karantana A, Bannister GC. Revision for recurrent dislocation of total hip replacement. *Hip Int*. 2009;19:109-13.
- 144.** Williamson JB, Galasko CS, Rowley DI. Failure of acetabular augmentation for recurrent dislocation after hip replacement. Report of 3 cases. *Acta Orthop Scand*. 1989;60:676-7.
- 145.** Beaulé PE, Schmalzried TP, Udomkiat P, Amstutz HC. Jumbo femoral head for the treatment of recurrent dislocation following total hip replacement. *J Bone Joint Surg Am*. 2002;84:256-63.
- 146.** Skeels MD, Berend KR, Lombardi AV Jr. The dislocator, early and late: the role of large heads. *Orthopedics*. 2009;32. pii: orthosupersite.com/view.asp?rID=42837.
- 147.** Barbosa JK, Khan AM, Andrew JG. Treatment of recurrent dislocation of total hip arthroplasty using a ligament prosthesis. *J Arthroplasty*. 2004;19:318-21.
- 148.** Lavigne MJ, Sanchez AA, Coutts RD. Recurrent dislocation after total hip arthroplasty: treatment with an Achilles tendon allograft. *J Arthroplasty*. 2001;16(8 Suppl 1):13-8.
- 149.** Strømme K, Eikvar K. Fascia lata plasty in recurrent posterior dislocation after total hip arthroplasty. *Arch Orthop Trauma Surg*. 1995;114:292-4.
- 150.** Dennis DA, Lynch CB. Trochanteric osteotomy and advancement: a technique for abductor related hip instability. *Orthopedics*. 2004;27:959-61.
- 151.** Kaplan SJ, Thomas WH, Poss R. Trochanteric advancement for recurrent dislocation after total hip arthroplasty. *J Arthroplasty*. 1987;2:119-24.
- 152.** Della Valle CJ, Berger RA, Rosenberg AG, Jacobs JJ, Sheinkop MB, Paprosky WG. Extended trochanteric osteotomy in complex primary total hip arthroplasty. A brief note. *J Bone Joint Surg Am*. 2003;85:2385-90.
- 153.** Attarian DE. Bipolar arthroplasty for recurrent total hip instability. *J South Orthop Assoc*. 1999;8:249-53.
- 154.** Ries MD, Wiedel JD. Bipolar hip arthroplasty for recurrent dislocation after total hip arthroplasty. A report of three cases. *Clin Orthop Relat Res*. 1992;278:121-7.
- 155.** Beaulé PE, Roussignol X, Schmalzried TP, Udomkiat P, Amstutz HC, Dujardin FH. [Tri-polar arthroplasty for recurrent total hip prosthesis dislocation]. *Rev Chir Orthop Reparatrice Appar Mot*. 2003;89:242-9. French.
- 156.** Grigoris P, Grecula MJ, Amstutz HC. Tri-polar hip replacement for recurrent prosthetic dislocation. *Clin Orthop Relat Res*. 1994;304:148-55.
- 157.** Levine BR, Della Valle CJ, Deirmengian CA, Breien KM, Weeden SH, Sporer SM, Paprosky WG. The use of tri-polar articulation in revision total hip arthroplasty: a minimum of 24 months' follow-up. *J Arthroplasty*. 2008;23:1182-8.
- 158.** Anderson MJ, Murray WR, Skinner HB. Constrained acetabular components. *J Arthroplasty*. 1994;9:17-23.
- 159.** Berend KR, Lombardi AV Jr, Mallory TH, Adams JB, Russell JH, Groseth KL. The long-term outcome of 755 consecutive constrained acetabular components in total hip arthroplasty examining the successes and failures. *J Arthroplasty*. 2005;20(7 Suppl 3):93-102.
- 160.** Berend KR, Lombardi AV Jr, Welch M, Adams JB. A constrained device with increased range of motion prevents early dislocation. *Clin Orthop Relat Res*. 2006;447:70-5.
- 161.** Bremner BR, Goetz DD, Callaghan JJ, Capello WN, Johnston RC. Use of constrained acetabular components for hip instability: an average 10-year follow-up study. *J Arthroplasty*. 2003;18(7 Suppl 1):131-7.
- 162.** Callaghan JJ, O'Rourke MR, Goetz DD, Lewallen DG, Johnston RC, Capello WN. Use of a constrained tri-polar acetabular liner to treat intraoperative instability and postoperative dislocation after total hip arthroplasty: a review of our experience. *Clin Orthop Relat Res*. 2004;429:117-23.
- 163.** Callaghan JJ, Parvizi J, Novak CC, Bremner B, Shrader W, Lewallen DG, Johnston RC, Goetz DD. A constrained liner cemented into a secure cementless acetabular shell. *J Bone Joint Surg Am*. 2004;86:2206-11.
- 164.** Goetz DD, Bremner BR, Callaghan JJ, Capello WN, Johnston RC. Salvage of a recurrently dislocating total hip prosthesis with use of a constrained acetabular component. A concise follow-up of a previous report. *J Bone Joint Surg Am*. 2004;86:2419-23.
- 165.** Goetz DD, Capello WN, Callaghan JJ, Brown TD, Johnston RC. Salvage of a recurrently dislocating total hip prosthesis with use of a constrained acetabular component. A retrospective analysis of fifty-six cases. *J Bone Joint Surg Am*. 1998;80:502-9.
- 166.** Goetz DD, Capello WN, Callaghan JJ, Brown TD, Johnston RC. Salvage of total hip instability with a constrained acetabular component. *Clin Orthop Relat Res*. 1998;355:171-81.
- 167.** Lombardi AV Jr, Mallory TH, Kraus TJ, Vaughn BK. Preliminary report on the S-ROM constraining acetabular insert: a retrospective clinical experience. *Orthopedics*. 1991;14:297-303.
- 168.** Padgett DE, Warashina H. The unstable total hip replacement. *Clin Orthop Relat Res*. 2004;420:72-9.
- 169.** Shrader MW, Parvizi J, Lewallen DG. The use of a constrained acetabular component to treat instability after total hip arthroplasty. *J Bone Joint Surg Am*. 2003;85:2179-83.
- 170.** Su EP, Pellicci PM. The role of constrained liners in total hip arthroplasty. *Clin Orthop Relat Res*. 2004;420:122-9.
- 171.** Kaper BP, Bernini PM. Failure of a constrained acetabular prosthesis of a total hip arthroplasty. A report of four cases. *J Bone Joint Surg Am*. 1998;80:561-5.
- 172.** Fisher DA, Kiley K. Constrained acetabular cup disassembly. *J Arthroplasty*. 1994;9:325-9.
- 173.** Guyon O, Lewallen DG, Cabanela ME. Modes of failure of Osteonics constrained tri-polar implants: a retrospective analysis of forty-three failed implants. *J Bone Joint Surg Am*. 2008;90:1553-60.
- 174.** Robertson WJ, Mattern CJ, Hur J, Su EP, Pellicci PM. Failure mechanisms and closed reduction of a constrained tri-polar acetabular liner. *J Arthroplasty*. 2009;24:322.e5-11.
- 175.** McPherson EJ, Costigan WM, Gerhardt MB, Norris LR. Closed reduction of dislocated total hip with S-ROM constrained acetabular component. *J Arthroplasty*. 1999;14:882-5.