



SELECTED  
**INSTRUCTIONAL  
COURSE LECTURES**

---

**THE AMERICAN ACADEMY OF ORTHOPAEDIC SURGEONS**

**PAUL TORNETTA III**

EDITOR, VOL. 61

**COMMITTEE**

**PAUL TORNETTA III**

CHAIR

**KENNETH A. EGOL**

**MARY I. O'CONNOR**

**MARK PAGNANO**

**ROBERT A. HART**

**EX-OFFICIO**

**DEMPSEY S. SPRINGFIELD**

DEPUTY EDITOR OF THE JOURNAL OF BONE AND JOINT SURGERY  
FOR INSTRUCTIONAL COURSE LECTURES

*Printed with permission of the American Academy of Orthopaedic Surgeons. This article, as well as other lectures presented at the Academy's Annual Meeting, will be available in February 2012 in Instructional Course Lectures, Volume 61. The complete volume can be ordered online at [www.aaos.org](http://www.aaos.org), or by calling 800-626-6726 (8 A.M.-5 P.M., Central time).*



# How to Do a Revision Total Hip Arthroplasty: Revision of the Acetabulum

Scott M. Sporer, MD, MS

*An Instructional Course Lecture, American Academy of Orthopaedic Surgeons*

The most common indications for acetabular revision include instability, infection, polyethylene wear, and aseptic loosening<sup>1</sup>. The prevalence of these conditions remains essentially unchanged despite improved prosthetic component designs and enhanced surgical techniques. A successful acetabular revision must provide intimate contact between the acetabular implant and the host bone, a stable mechanical construct minimizing micromotion to allow bone ingrowth into a cementless acetabular component, and a mechanical construct that distributes the physiologic stresses to the surrounding acetabular bone. Additionally, the acetabular reconstruction must allow appropriate component

orientation to minimize the risk of dislocation and reestablish the anatomic hip center to improve the overall joint kinematics. Biologic methods of acetabular reconstruction are advised except in cases of severe bone loss or prior radiation treatment in the hip region, since nonbiologic revisions eventually fail<sup>2</sup>. Periacetabular bone loss can compromise component fixation, resulting in early loosening of the revised acetabulum. The amount of bone loss undoubtedly influences the ability to obtain initial optimal fixation. The location of remaining supportive bone, however, has a more important role in providing durable fixation than does the quantity of bone loss.

## Defect Classification Systems

Acetabular defect classification systems can be used to predict the extent of bone loss seen intraoperatively and guide subsequent reconstructive options. The three most common classification systems for acetabular defects are the American Academy of Orthopaedic Surgeons (AAOS) classification system described by D'Antonio et al.<sup>3</sup> (Table I), the Gross classification system described by Saleh et al.<sup>4</sup> (Table II), and the Paprosky classification system<sup>5</sup> (Table III). The AAOS classification system identifies the pattern of acetabular bone loss, but does not quantify the size or location of the defect. Despite being the most commonly cited, the AAOS defect classification system does not guide the identification of reconstructive options. The system described by Saleh et al. is based on the degree of bone loss seen on preoperative standard anteroposterior and lateral radiographs of the hip. A bone defect is considered uncontained if morselized bone graft cannot be used to fill the defect. The Paprosky classification system is based on four

**Look for this and other related articles in *Instructional Course Lectures, Volume 61*, which will be published by the American Academy of Orthopaedic Surgeons in February 2012:**

- “Femoral Fixation in Revision Total Hip Arthroplasty,” by Curtis W. Hartman, MD, and Kevin L. Garvin, MD

**Disclosure:** The author did not receive payments or services, either directly or indirectly (i.e., via his institution), from a third party in support of any aspect of this work. He, or his institution, has had a financial relationship, in the thirty-six months prior to submission of this work, with an entity in the biomedical arena that could be perceived to influence or have the potential to influence what is written in this work. The author has not had any other relationships, or engaged in any other activities, that could be perceived to influence or have the potential to influence what is written in this work. The complete **Disclosures of Potential Conflicts of Interest** submitted by the author of this work are available with the online version of this article at [jbjs.org](http://jbjs.org).

**TABLE I AAOS Classification System for Acetabular Defects<sup>3\*</sup>**

Type	Description
I	Segmental defect
II	Cavitary defect
III	Combined segmental and cavitary defect
IV	Pelvic discontinuity
IVa	Discontinuity with mild segmental or cavitary bone loss
IVb	Discontinuity with moderate-to-severe segmental or cavitary bone loss
IVc	Discontinuity with prior pelvic irradiation
V	Hip arthrodesis

\*AAOS = American Academy of Orthopaedic Surgeons.

**TABLE II Gross Classification System for Acetabular Defects Described by Saleh et al.<sup>4</sup>**

Type	Description
I	No substantial loss of bone stock
II	Contained loss of bone stock (columns and/or rim intact)
III	Uncontained loss of bone stock (<50% acetabulum)
IV	Uncontained loss of bone stock (>50% acetabulum)
V	Contained loss of bone stock with pelvic discontinuity

**TABLE III Paprosky Classification System for Acetabular Defects<sup>5</sup>**

Type	Description			
	Femoral Head Center Migration	Ischial Osteolysis	Kohler Line	Teardrop
I	Minimal (<3 cm)	None	Intact	Intact
IIA	Mild (<3 cm)	Mild	Intact	Intact
IIB	Moderate (<3 cm)	Mild	Intact	Intact
IIC	Mild (<3 cm)	Mild	Disrupted	Moderate lysis
IIIA	Severe (>3 cm)	Moderate	Intact	Moderate lysis
IIIB	Severe (>3 cm)	Severe	Disrupted	Severe lysis

radiographic criteria from an antero-posterior pelvic radiograph: (1) superior migration of the hip center, (2) ischial osteolysis, (3) acetabular teardrop osteolysis, and (4) position of the implant relative to the Kohler line<sup>5</sup> (Fig. 1). Superior migration of the hip center represents bone loss of the acetabular dome involving the anterior and posterior columns. Ischial osteolysis indicates bone loss from the posterior column including the posterior wall, while teardrop osteolysis and migration beyond the Kohler line represent medial acetabular bone loss.

Type-III defects require structural support from bulk allograft, metallic augmentation, an acetabular cage, or a custom acetabular component. The Paprosky classification system is often used clinically, as it not only predicts bone loss encountered intraoperatively but also assists in determining reconstructive options.

### Component Removal

Successful acetabular reconstruction begins with a meticulous surgical technique to remove a well-fixed acetabular component. The use of acetabular “ex-

plant osteotomes” (Fig. 2) facilitates the safe removal of well-fixed components. An osteotome blade, which is the outer diameter of the acetabular component, is used with a so-called femoral head that matches the diameter of the bearing surface. The osteotome is rotated around the periphery of the socket, disrupting the interface between the implant and the host bone. Areas of the pelvis that are crucial for subsequent reconstruction are the anterosuperior and posteroinferior aspects of the acetabulum. Monoblock acetabular components are removed with use of a so-called bipolar articulation with a curved osteotome blade matching the outer diameter of the acetabular component. Alternatively, manual instruments such as curved chisels and motorized burrs can be used to disrupt the prosthesis-bone interface or section the cup. One should avoid the temptation to forcefully manipulate the component during removal as severe bone loss and associated pelvic discontinuity may occur. A preoperative angiogram and/or vascular surgery consultation should be obtained if the acetabular component has migrated medially past the Kohler line (Fig. 3).

### Treatment Algorithm

The treatment of acetabular defects depends on the degree and location of bone loss in addition to the potential for biologic fixation. Prior irradiation of the pelvis can result in periacetabular osteonecrosis with limited in-growth potential<sup>2</sup>. In these situations, nonbiologic fixation options, such as acetabular cages, custom implants, and fixed-angled devices, which off-load the host bone, should be considered. Fortunately, the majority of acetabular revisions can be managed successfully with a hemispherical component alone<sup>6-9</sup>. The goals of revision surgery are to obtain stable fixation on the remaining host bone and to restore the hip center with the acetabular component near the Kohler line and the inferomedial aspect of the acetabular component near the inferior portion of the acetabular teardrop. An algorithmic approach to

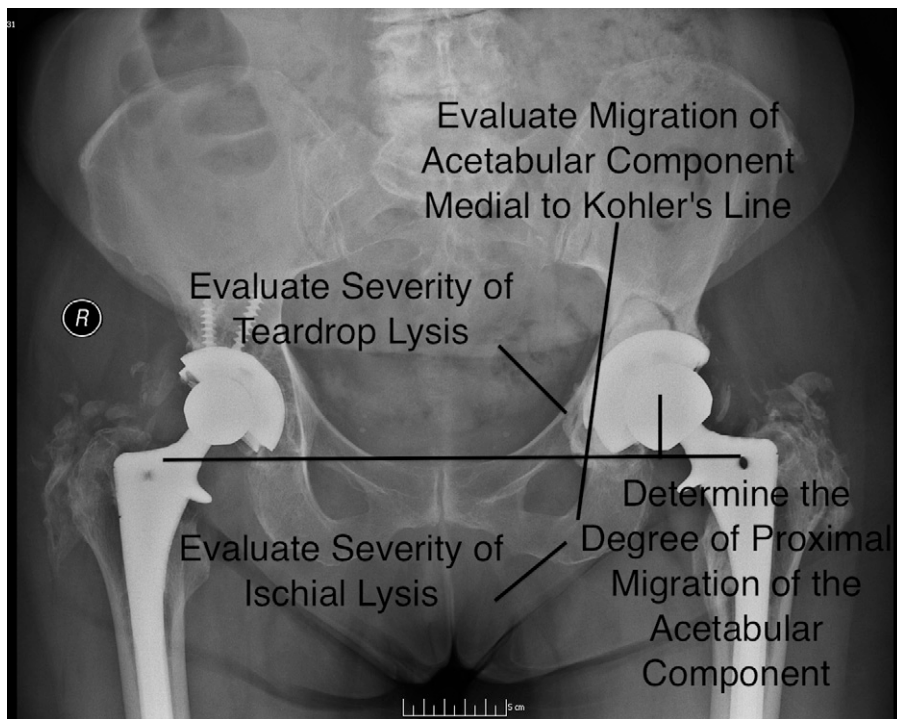


Fig. 1  
Components of the radiographic criteria in the Paprosky classification system for acetabular defects.

acetabular defects helps both preoperative planning as well as surgical decision-making (Fig. 4).

### Acetabular Reconstruction

**Hemispherical or Elliptical Component**  
An acetabular component with a hemispherical or elliptical design can be used in patients when the hip center of rotation has not migrated  $>3$  cm proximally (Paprosky Types I, IIA, IIB, and IIC)<sup>10,11</sup>. After acetabular component removal, the remaining host bone should be exposed and all granulation tissue thoroughly debrided. Pelvic discontinuity is assessed by looking for motion between the superior and the inferior hemipelvis when applying a caudal stress to the ischium with a Cobb elevator.

A retractor is placed in the obturator foramen to determine the level of the true acetabulum, which is the level of the inferior border of the acetabulum. Sequentially larger hemispherical acetabular reamers are used to determine the size of the acetabulum until the anterior and posterior columns are engaged by the reamer. To minimize the

likelihood of creating pelvic discontinuity while reaming, in general, anterior acetabular bone should be sacrificed before posterior column bone. Trial acetabular components are used to assess the stability of the acetabular socket along with the degree of component coverage. Most acetabular defects have 5% to 20% of the acetabular component uncovered posterosuperiorly if the trial cup is placed in  $40^\circ$  of vertical inclination and  $15^\circ$  of anteversion. One should avoid the temptation to place the component more vertically to improve coverage as this can increase the risk of dislocation and wear. Cavitary bone defects are packed with either local autograft or allograft with use of a reamer 2 mm smaller than the last reaming in reverse. An acetabular component that is 2 mm larger at the periphery than the last reamer is used in most patients to obtain a so-called press-fit and initial fixation. Supplemental fixation with multiple screws is advised in all revisions to minimize micromotion and promote bone ingrowth. Screws should be placed not only postero-

superiorly into the dome of the acetabulum but also inferiorly into the ischium.

### Surgical Treatment of Type-III A Defects

Proximal and lateral migration of the acetabular component of  $>3$  cm results in an acetabular dome deficiency that does not provide enough stability for a hemispherical acetabular component alone. Treatment options for patients with superior segmental bone loss include the use of structural bulk allograft, dual-geometry monoblock components, hemispherical components with metallic superior augmentation, or placement of an implant with a high hip center. A high hip center places the hip abductor muscles at a mechanical disadvantage and necessitates the use of a small acetabular component. It can be challenging to obtain stable fixation and appropriate component orientation with use of a monoblock dual-geometry acetabular component<sup>12,13</sup>. I prefer to use a hemispherical acetabular component placed at the level of the true acetabulum and to create superior cup coverage with the use of metallic augmentation.



Fig. 2  
Acetabular component extraction tool. A bipolar femoral head may be used to remove a monoblock cobalt-chromium acetabular component. (Reprinted, with permission, from Taylor PR, Stoffel KK, Dunlop DG, Yates PJ. Removal of the well-fixed hip resurfacing acetabular component: a simple, bone preserving technique. *J Arthroplasty*. 2009;24:484-6.)

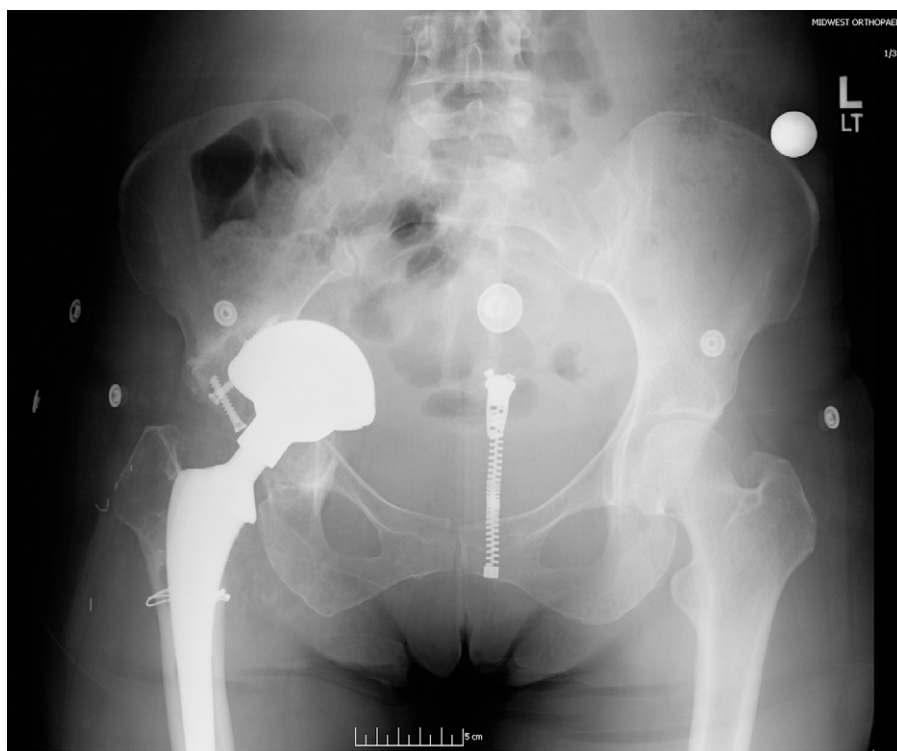

Fig. 3  
Intrapelvic migration of the acetabular component—a Paprosky Type-IIIIB defect. A preoperative angiogram or vascular surgery consultation should be considered to minimize the risk of injury to the iliac vessel during revision arthroplasty.

### *Hemispherical Component with Metallic Augmentation*

The surgical treatment of a superior segmental bone defect with a hemispherical shell and augment begins by identifying the location of the true acetabulum with a retractor placed into the obturator foramen. Hemispherical reamers are then used to ream in the anatomic position until the anterior and posterior columns are engaged, which results in partial stability of a trial acetabular component. A superior augment is used either as a buttress in patients with primarily segmental bone loss or as a superior graft in patients with primarily oblong cavitory bone loss (Figs. 5-A, 5-B, and 5-C). It is crucial that the position of the augment not influence the ultimate position of the acetabular component. With the trial component in place, the augment is secured to the host bone with screws. The augment is then packed with bone graft, leaving the portion facing the cup exposed. Polymethylmethacrylate ce-

ment is placed directly on the porous revision cup only in the areas mating with the augment. The acetabular component is firmly impacted to achieve a press-fit against the host bone. In severe bone loss, the polyethylene liner can be cemented into the acetabular shell in order to place screws at a fixed angle. Multiple screws are used in different planes to maximize stability and minimize the likelihood of component loosening<sup>14</sup>.

### *Hemispherical Component with Distal Femoral Allograft*

The use of bulk allograft has been largely abandoned except in young patients because of the increased surgical time, need for more soft-tissue exposure, and concern for graft resorption<sup>15</sup>. Similar to metallic augmentation, the first step in the acetabular reconstruction with bulk allograft is to identify the location of the desired hip center and to utilize acetabular reamers to size and shape the anteroposterior dimensions of the ac-

etabulum to accept a hemispherical cementless implant. The distal femoral allograft is prepared to accommodate the segmental dome defect once it has been determined that there is inadequate coverage of a hemispherical component. The cortex of the distal femoral allograft shaft in the coronal plane relative to the condyles is removed. The posterior aspect of the condyles is then shaped to correspond with the superior acetabular defect with use of a female reamer measuring 2 mm larger than the last reamer used to size the defect. The anterior-to-posterior aspect of the distal femoral allograft should correspond to the medial-to-lateral depth of the defect. The superior cortical limb of the graft should be approximately 4 to 5 cm to allow adequate fixation to the lateral aspect of the ilium. The contoured graft is impacted into the superior defect, obtaining a press-fit. The allograft is secured with three or four parallel 6.5-mm cancellous screws with washers. The screws are oriented obliquely into the ilium in the direction of loading to provide compression of the graft against the remaining ilium. The acetabular cavity is reamed to contour the portion of the graft that will contact the hemispherical component<sup>16</sup> (Fig. 6).

### *Surgical Treatment of Type-III B Defects*

Proximal and medial migration of the acetabular component of >3 cm results in an acetabular dome deficiency as well as a medial wall deficiency that does not provide enough intrinsic stability for a hemispherical acetabular component alone. Treatment options for patients with superomedial segmental bone loss include structural bulk allograft, custom implants spanning the iliac wing to the ischium, hemispherical components with multiple metal augments, or an acetabular cage. Pelvic discontinuity frequently occurs in patients with severe proximal medial migration of the acetabular component.

### *Acetabular Transplant with Cage*

Acetabular reamers are used to size the acetabular cavity and identify the location of remaining bone along the superior aspect of the ilium that will abut

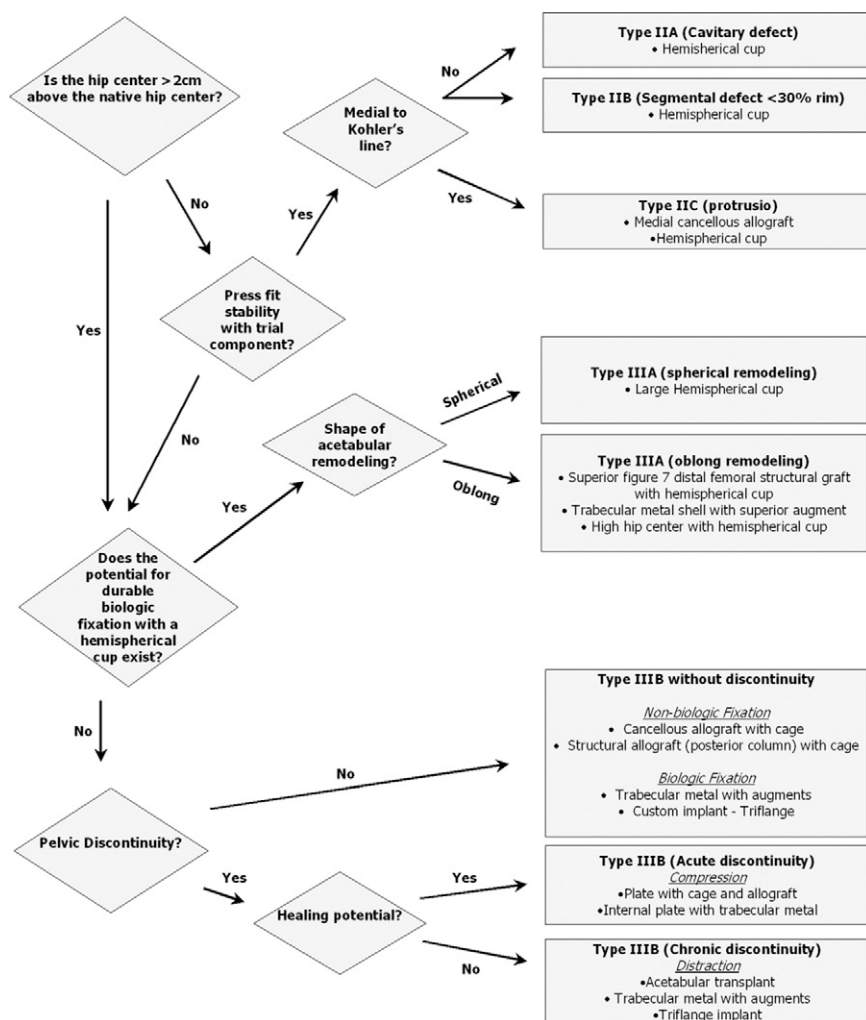


Fig. 4  
Treatment algorithm for acetabular revision surgery. (Reprinted, with permission, from: Paprosky WG. Acetabular revision. New York: Springer; 2005.)

the allograft. The acetabulum of the hemipelvic allograft is reamed on the back table to accept the cage. A curvilinear osteotomy is made in the allograft from the greater sciatic notch to the anterior superior iliac spine. The pubic and ischial portions of the allograft are removed distal to the confluence of the acetabulum with enough length to accommodate any inferior defects. One should avoid leaving excessive inferior bone on the allograft that may prevent optimal medialization of the graft, which leads to subsequent vertical cup placement and lateralization of the hip center. A female reamer, 1 to 2 mm larger than the acetabular reamer used to size the acetabulum, should be used to mark and shape the medial aspect of

the graft to fit the defect. A groove is made in the superior aspect of the ilium of the allograft to correspond to the ledge of bone along the superior aspect of the native acetabulum. This tongue-and-groove junction provides a stable buttress between the host and the allograft. A burr is used to debulk the inner table of the allograft ilium, while a shelf that will fill the defect of the acetabulum is maintained distally. The graft is secured with Steinmann pins provisionally until four 6.5-mm partially threaded screws are placed obliquely into the ilium from both the intra-articular and lateral aspects of the ilium of the graft. A pelvic reconstruction plate contoured to the posterior column with three screws in the

native ilium and ischium is used for fixation. A cage is recommended to protect all transplants, and if possible, the inferior flange of a cage is inserted into a slot in the ischium for fixation. A metal shell or a polyethylene liner is cemented into the cage-allograft composite, with care taken to avoid the tendency to place the acetabular component in a vertical and retroverted position.

### Type-III B Defect: Modular Metal Augmentation

The acetabulum is reamed in the anatomical location and direction (anterior to posterior, anterior-inferior to posterior-inferior, or posterior-superior to anterior-inferior) for the eventual reconstruction until two points of fixation are achieved, as this determines the size of the acetabular defect. Acetabular augments are used to decrease the acetabular volume and restore a rim to support a revision cup. The location and orientation of augments depends on the pattern of bone loss. Augments are frequently placed along the medial aspect of the ilium or are stacked together to reconstruct the superomedial defect. It is more common to use augments with the wide base placed laterally and the apex medially, which is the opposite of how the augments are often used in the Type-III A defect. The revision acetabular cup directly contacts the augments, and the augments are necessary to achieve a press-fit of the acetabular component. Similar to the treatment of a Type-III A defect, augments for a Type-III B defect are initially secured to the host bone with the use of multiple screws. Portions of the augments are removed with a burr or a reamer as needed to optimize the surface area contact between the revision shell and the augments. Particulate bone graft is placed into any remaining cavities before the hemispherical revision shell is impacted in place. Similar to the treatment of a Type-III A defect, the interface between the revision shell and the augment is cemented to minimize micromotion and subsequent fretting. Multiple screws into both the ilium and ischium are used for fixation.



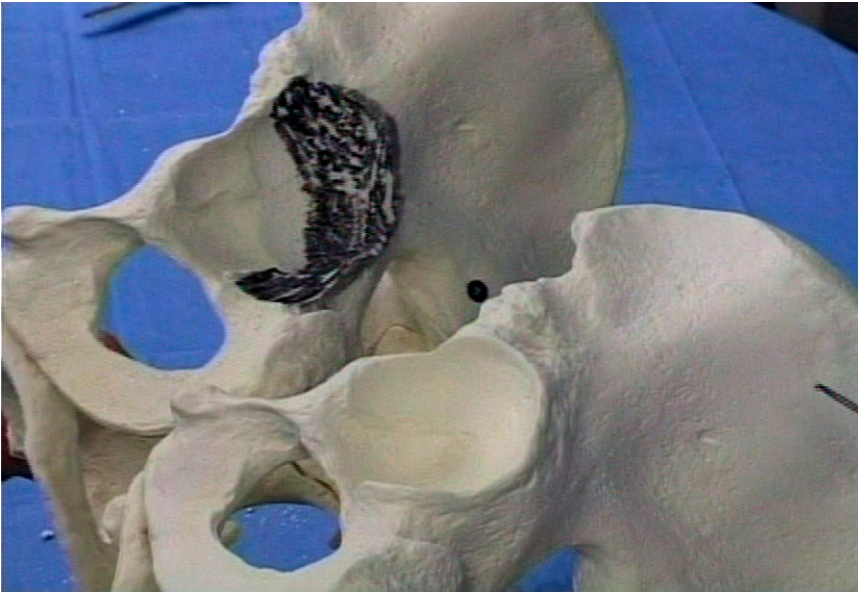


Fig. 5-A

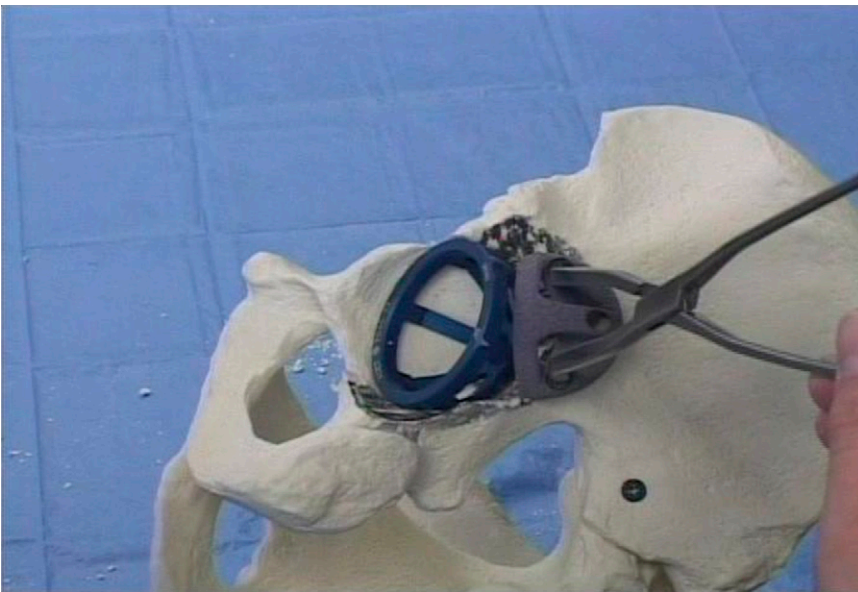

Fig. 5-B

**Fig. 5-A** Type-III acetabular defect with superior and posterior bone loss. **Fig. 5-B** Acetabular augment used as a buttress to provide additional superior coverage.

### *Pelvic Discontinuity*

A hemispherical acetabular component alone does not provide adequate implant stability in patients with a pelvic discontinuity. Treatment options for a pelvic discontinuity include compression plating of the posterior column with use of a hemispherical component, placement of an acetabular cage, use of a custom implant that spans the discontinuity, or use of metal acetabular aug-

ments to “distract” across the pelvic discontinuity<sup>17</sup>. In patients with a chronic pelvic discontinuity, the amount of bone loss along the posterior column is often too severe to provide direct bone apposition during compression plating.

### *Modular Metal Augmentation with Distraction for Pelvic Discontinuity*

The goal of the distraction technique for a pelvic discontinuity is to use

ligamentotaxis secondary to the lengthening across the discontinuity to provide initial component stability. The location and severity of bone loss determine the type and position of the acetabular augments used to enhance initial component stability. Acetabular augments are frequently used to reconstruct portions of the anterosuperior aspect of the acetabulum as well as the posteroinferior aspect of the acetabulum to provide two secure points of fixation for the acetabular component both cephalad and caudal to the discontinuity. A porous acetabular component, which is 6 to 8 mm larger than the hemispherical reamer that engaged the anterior and posterior columns, is used to distract the superior hemipelvis from the inferior hemipelvis. Multiple screws are placed into the remaining ilium and ischium through the acetabular shell, and the augments are secured to the cup with polymethylmethacrylate. A polyethylene liner is cemented into the acetabular component, allowing screws to be placed at a fixed angle. A successful reconstruction of a pelvic discontinuity requires ingrowth of the host bone into both the superior and inferior portions of the acetabular component to bridge the discontinuity. Consequently, one must obtain as much contact between the host bone and the porous augments and acetabular component as possible.

### **Tips and Pearls for Acetabular Revision**

#### *Paprosky Type-IIB Defects*

- Ream until the anterior and posterior columns are engaged, to allow intrinsic stability of the trial component.
- Ream slightly superiorly to improve coverage.
- Avoid attempts to provide coverage of the superior dome—the superior portion of the acetabular component may remain uncovered.
- Reverse ream with a reamer that is 1 to 2 mm undersized to pack cavity defects.
- Use a cup with multiple holes.
- Avoid a spiked cup.

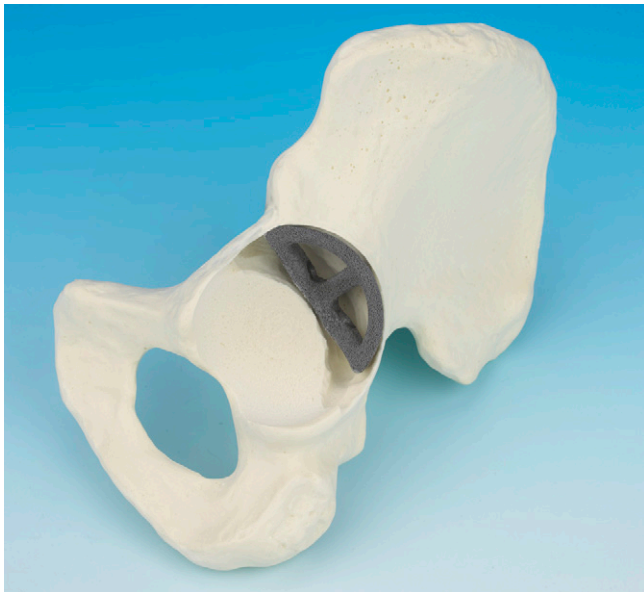

Fig. 5-C  
Augment used as a cavitary graft to fill cavitary bone defect and lower hip center.

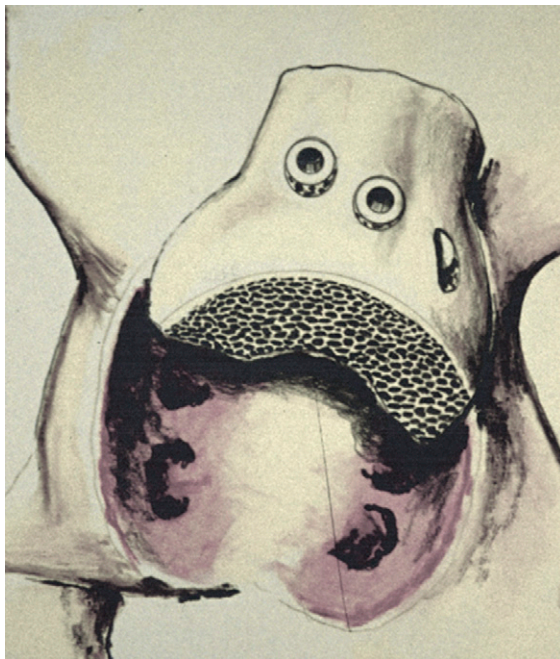

Fig. 6  
Distal femoral structural allograft used to reconstruct the superior dome of the acetabulum. (Reprinted from: Sporer SM, O'Rourke M, Chong P, Paprosky WG. The use of structural distal femoral allografts for acetabular reconstruction. Average ten-year follow-up. J Bone Joint Surg Am. 2005;87:760-5.)

#### **Paprosky Type-IIC Defects**

- Ream until the anterior and posterior columns are engaged, to allow intrinsic stability of trial cup along the acetabular rim.
- Medial bone graft is added until the reverse reamer, which is 1 to 2 mm

undersized, disengages from the drive shaft.

- Use an acetabular component that is 2 mm larger than the last reamer to achieve press-fit fixation.
- Use a cup with multiple holes.

#### **Paprosky Type-III A Defects—Distal Femoral Allograft**

- Verify that the surgical site is free of infection before opening the distal femoral allograft.
- Culture the femoral allograft.
- Avoid the use of femoral head allograft.
- Elevate abductor musculature with use of a Taylor retractor to allow adequate visualization of the iliac wing.
- Cut a figure-7-shaped portion of allograft at slightly less than 90° to allow intrinsic stability.
- Use 6.5-mm cancellous screws and always use with a washer.
- Tap screws in the allograft to avoid fracture.
- Avoid the tendency to place the component in excessive abduction and retroversion, i.e., the cup may remain uncovered.
- Place screws through cup-allograft-host bone if possible.

#### **Paprosky Type-III A Defects—Hemispherical Component with Metal Augment**

- Progressively ream in the anatomic position to engage the anterior and posterior columns to allow intrinsic stability to the acetabular trial.
- Place the superior augment with the trial component in place (with appropriate version and abduction). The augment can be placed in any position or orientation to allow improved initial stability. Leave 1 to 2 mm between the cup and the augment for the placement of cement.
- Use a motorized burr along the superior dome to fit the host bone to the augment to improve intrinsic stability and maximize bone contact.
- Pack the augment with bone graft, leaving the metal of the augment that faces the cup exposed.
- Place cement directly onto the porous revision cup only in areas mating with the augment.
- Insert the cup with cement in the doughy phase to improve interdigitation between the cup and the augment.
- Consider the use of cement with antibiotics.



- Before the cement hardens, attempt to place a screw in the revision cup to eliminate motion during the final seating of the screws.

- Place bone wax in the end of the screws to facilitate cup removal.

### Paprosky Type-IIIB

#### Defects—Hemispherical Component with Metal Augment and No Discontinuity

- Use augments to reconstruct the pelvis with nonbiologic material.
- Expose all margins of the acetabular defect.

- Progressively ream (anterior-posterior, anterior-inferior, and posterior-inferior) until two points of fixation are achieved.

- Loss of inferior bone stock (ischium) is often involved.

- Intrinsic stability will not be obtained with the trial component.

- Use augments to decrease acetabular volume and facilitate press-fit between the cup and the augment, i.e., attempt to place the augment in direct contact with the revision cup.

- Secure the augment first.

- Reverse ream with the augment in place to pack the bone graft.

- Clear bone graft from the exposed host bone, i.e., maximize the contact area between the host bone and the revision porous cup.

- Attempt to place screws inferiorly into the ischium to avoid cup pullout.

### Paprosky Type-IIIB Defects—Pelvic Discontinuity Distraction

- Use a porous acetabular component to reconstruct the pelvis with biologic material as an internal fixation device.

- Expose all margins of the acetabular defect and discontinuity thoroughly.

- Progressively ream (anterior to posterior, anterior-inferior to posterior-inferior, or posterior-superior to anterior-inferior) until two points of fixation are achieved.

- Intrinsic stability will not be obtained.

- Use augments to decrease acetabular volume and facilitate press-fit between the cup and the augment, i.e., attempt to place the augment in direct contact with the revision cup.

- Bridge the discontinuity with the augment and place screws cephalad and caudal to the discontinuity.

- Remove fibrous tissue in the discontinuity and place the bone graft.

- Reverse ream with the augment in place to pack the bone graft.

- Clear bone graft from exposed host bone, i.e., maximize contact area between the host bone and the revision cup.

Scott M. Sporer, MD, MS  
Department of Orthopaedic Surgery,  
Rush University Medical Center,  
25 North Winfield Road, Suite 505,  
Winfield, IL 60190.

Printed with permission of the American Academy of Orthopaedic Surgeons. This article, as well as other lectures presented at the Academy's Annual Meeting, will be available in February 2012 in *Instructional Course Lectures*, Volume 61. The complete volume can be ordered online at [www.aaos.org](http://www.aaos.org), or by calling 800-626-6726 (8 a.m.-5 p.m., Central time).

## References

1. Bozic KJ, Kurtz SM, Lau E, Ong K, Vail TP, Berry DJ. The epidemiology of revision total hip arthroplasty in the United States. *J Bone Joint Surg Am.* 2009;91:128-33.
2. Jacobs JJ, Kull LR, Frey GA, Gitelis S, Sheinkop MB, Kramer TS, Rosenberg AG. Early failure of acetabular components inserted without cement after previous pelvic irradiation. *J Bone Joint Surg Am.* 1995;77:1829-35.
3. D'Antonio JA, Capello WN, Borden LS, Bargar WL, Bierbaum BF, Boettcher WG, Steinberg ME, Stulberg SD, Wedge JH. Classification and management of acetabular abnormalities in total hip arthroplasty. *Clin Orthop Relat Res.* 1989;243:126-37.
4. Saleh KJ, Holtzman J, Gafni ASaleh L, Jaroszynski G, Wong P, Woodgate I, Davis A, Gross AE. Development, test reliability and validation of a classification for revision hip arthroplasty. *J Orthop Res.* 2001;19:50-6.
5. Paprosky WG, Perona PG, Lawrence JM. Acetabular defect classification and surgical reconstruction in revision arthroplasty. A 6-year follow-up evaluation. *J Arthroplasty.* 1994;9:33-44.
6. Della Valle CJ, Berger RA, Rosenberg AG, Galante JO. Cementless acetabular reconstruction in revision total hip arthroplasty. *Clin Orthop Relat Res.* 2004;420:96-100.
7. Gaffey JL, Callaghan JJ, Pedersen DR, Goetz DD, Sullivan PM, Johnston RC. Cementless acetabular fixation at fifteen years. A comparison with the same surgeon's results following acetabular fixation with cement. *J Bone Joint Surg Am.* 2004;86:257-61.
8. Hallstrom BR, Golladay GJ, Vittetoe DA, Harris WH. Cementless acetabular revision with the Harris-Galante porous prosthesis. Results after a minimum of ten years of follow-up. *J Bone Joint Surg Am.* 2004;86:1007-11.
9. Templeton JE, Callaghan JJ, Goetz DD, Sullivan PM, Johnston RC. Revision of a cemented acetabular component to a cementless acetabular component. A ten to fourteen-year follow-up study. *J Bone Joint Surg Am.* 2001;83:1706-11.
10. Leopold SS, Rosenberg AG, Bhatt RD, Sheinkop MB, Quigley LR, Galante JO. Cementless acetabular revision. Evaluation at an average of 10.5 years. *Clin Orthop Relat Res.* 1999;369:179-86.
11. Silverton CD, Rosenberg AG, Sheinkop MB, Kull LR, Galante JO. Revision total hip arthroplasty using a cementless acetabular component. Technique and results. *Clin Orthop Relat Res.* 1995;319:201-8.
12. Chen WM, Engh CA Jr, Hopper RH Jr, McAuley JP, Engh CA. Acetabular revision with use of a bilobed component inserted without cement in patients who have acetabular bone-stock deficiency. *J Bone Joint Surg Am.* 2000;82:197-206.
13. Schutzer SF, Harris WH. High placement of porous-coated acetabular components in complex total hip arthroplasty. *J Arthroplasty.* 1994;9:359-67.
14. Sporer SM, Paprosky WG. The use of a trabecular metal acetabular component and trabecular metal augment for severe acetabular defects. *J Arthroplasty.* 2006;21(6 Suppl 2):83-6.
15. Sporer SM, O'Rourke M, Chong P, Paprosky WG. The use of structural distal femoral allografts for acetabular reconstruction. Average ten-year follow-up. *J Bone Joint Surg Am.* 2005;87:760-5.
16. Sporer SM, O'Rourke M, Chong P, Paprosky WG. The use of structural distal femoral allografts for acetabular reconstruction. Surgical technique. *J Bone Joint Surg Am.* 2006;88 Suppl 1 Pt 1:92-9.
17. Paprosky WG, O'Rourke M, Sporer SM. The treatment of acetabular bone defects with an associated pelvic discontinuity. *Clin Orthop Relat Res.* 2005;441:216-20.